

Extreme Calvarial and Upper Cervical Hyperpneumatization: A Case Report

Ebru Dogan Doruk¹, Burak Eren¹, Ozgur Yusuf Aktas¹, Erhamit Okutan¹, Gunay Vahabova¹, Feyza Karagoz Guzey¹



ABSTRACT

The pneumatization of bones of cranial base other than the mastoid process and temporal bone is a pathologic and rare condition, and it may cause some serious complications. Extension of the pneumatization to the cranial vault and upper cervical bones is extremely rare.

A 67 year-old man was admitted with complaint of chronic nonspecific headache for a long time. He had no history of head trauma or otologic infection. Physical examination not revealed fever, any palpable swelling, rhinorrhea or otorrhea. There was only a slight right sensorineural hearing loss. Brain computerized tomography (CT) revealed hyperpneumatization in the right mastoid process and right temporal bone, bilateral occipital, parietal and frontal bones, and right side of the atlas. There was no pneumocephalus, but there was free air under the scalp of the right suboccipital region and around the right condyle, right transverse process of the atlas and right paravertebral region of the upper cervical vertebrae. Extrathecal cerebrospinal fluid (CSF) leakage was not detected by CT cisternography with intrathecal contrast administration and by the radionuclide cisternogram.

Keywords: Headache, cerebrospinal fluid, hyperpneumatization, pneumatocele, pneumocephalus

ÖZ

Kafatası ve üst servikal kemiklerde sıradışı hiperpnömatizasyon: Olgu sunumu

Mastoid çıkıntı ve temporal kemik dışındaki kafa tabanı kemiklerinin havalanması patolojik ve nadir bir durumdur ve ciddi komplikasyonlara neden olabilir. Havalanmanın kafa kubbesine ve üst boyun omurlarına uzanması çok nadirdir.

Uzun süredir devam eden, nonspesifik kronik baş ağrısı şikayetleri ile başvuran 67 yaşında erkek hastanın kafa travması ya da kulak enfeksiyon öyküsü yoktu. Muayenesinde ateş, ele gelen kitle, rinore ya da otore saptanmadı. Sadece sağda hafif sensorinöral işitme kaybı saptandı. Beyin bilgisayarlı tomografisinde (BT) sağ mastoid çıkıntı ve temporal kemikte ve iki yanlı oksipital, pariyetal ve frontal kemiklerde ve atlas sağ tarafında hiperpnömatizasyon izlendi. Kafa içinde hava yoktu, fakat sağ suboksipital bölgedeki kafa derisi altında, sağ kondil ve atlas sağ transvers çıkıntısı etrafında ve üst boyun omurlarının sağ tarafında serbest hava görünümü mevcuttu. İntratekal kontrast verilmesi sonrası BT sisternografide ve radionüklid sisternogramda ekstratekal beyin omurilik sıvısı kaçığı görülmüdü.

Anahtar kelimeler: Baş ağrısı, beyin omurilik sıvısı, hiperpnömatizasyon, pnömatosel, pnömoselali

¹Health Sciences University, Bagcilar Training and Research Hospital, Neurosurgery Clinic, Istanbul, Turkey

Corresponding author:

Feyza Karagoz Guzey,
Health Sciences University, Bagcilar Training and Research Hospital, Neurosurgery Clinic, Istanbul, Turkey
E-mail address: fkarag@yaho.com

Date of submission: September 05, 2018

Date of acceptance: September 10, 2018

Citation: Dogan-Doruk E, Eren B, Aktas OY, Okutan E, Vahabova G, Karagoz-Guzey F. Extreme calvarial and upper cervical hyperpneumatization: A case report. Bagcilar Medical Bulletin 2018;3(3):45-48. <https://doi.org/10.5350/BMB20180905123520>

Introduction

Hyperpneumatization of the mastoid, temporal and occipital bone is a rare condition (1-3), and its extension to the parietal and frontal bones, especially to the atlas is extremely rare (4). It has clinical importance because it may cause to extracranial pneumatocele or pneumocephalus, meningitis or cerebrospinal fluid fistulas spontaneously or after minor traumas (2).

We reported a very rare case with extreme hyperpneumatization of the right mastoid process and temporal bone, bilateral occipital, parietal, and even frontal bones and right side of the atlas.

Case Report

A 67 year old man was admitted with complaint of chronic nonspecific headache for a long time. He had no history of

head trauma, otitis media or vertigo. There was not repeated Valsalva maneuver history. Physical examination not revealed fever, feeling of fullness in the temporal region, any palpable swelling, rhinorrhea, or otorrhea. There was not any neurological finding except a slight right sensorineural hearing loss. Tympanic membrane was intact. CT scan revealed hyperpneumatization of the right mastoid process and temporal bone, bilateral occipital, and parietal bones, and right side of the atlas (Figure 1). Hyperpneumatization extended the parts of the bilateral frontal bones closing the coronary suture also (Figure 2). The air escaped from a small bony opening of the right suboccipital bone under the scalp, and also around the right condyle, right transverse process of the atlas and right paravertebral region of the upper cervical spine. There was not pneumocephalus. Extrathecal CSF leakage was not detected by CT cisternography with intrathecal contrast administration and by the radionuclide cisternography.

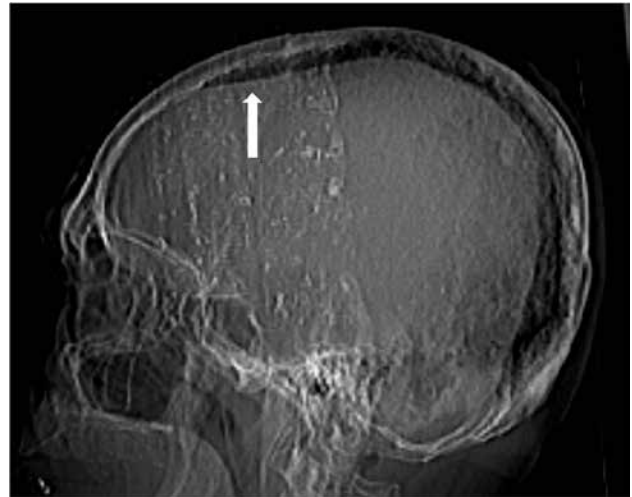


Figure 2: Lateral scannogram of the cranium showing that hyperpneumatization extended to the frontal bone (white arrow).

The patient was discharged after necessary recommendations because of absence of related complaints

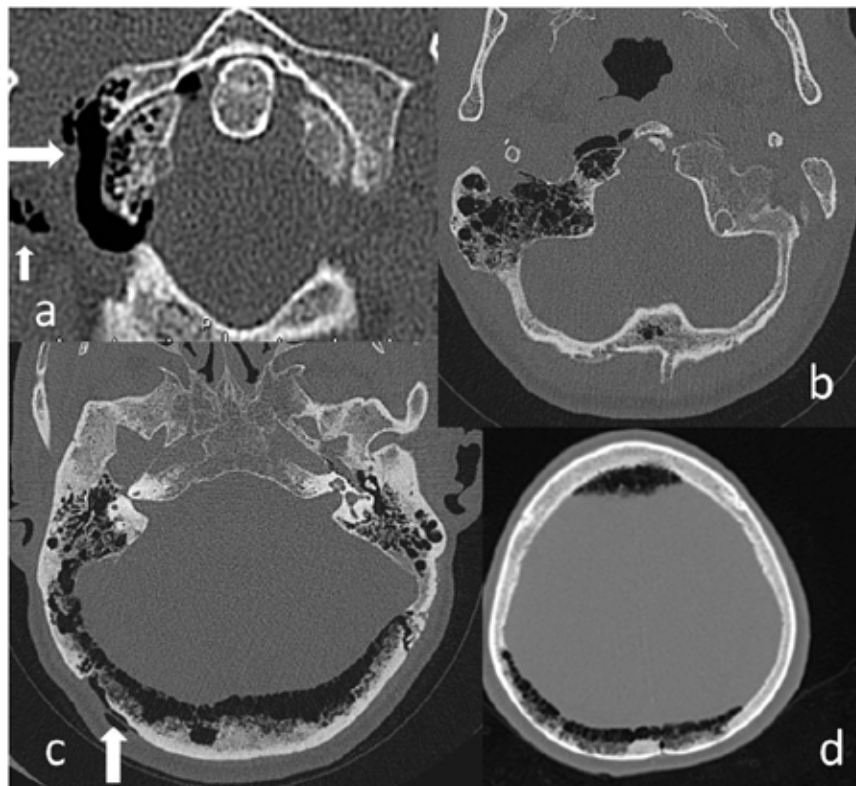


Figure 1: Axial cervical (a) and brain (b-d) sections of the CT. In (a), pneumatization of the right side of the atlas and free air around the right atlantooccipital joint (large white arrow) was seen. There was free air in soft tissue of the paravertebral region on same side also (small white arrow). Hyperpneumatization of the right mastoid bone, and right side of the foramen magnum (b), bilateral occipital bone (c), and bilateral parietal and frontal bones (d) was seen also. There was a small amount free air under the scalp of the right suboccipital region (white arrow in c).

and complications such as free air in the cranial space or CSF fistula. His follow-up was uneventful for 18 months.

A written consent was taken from the patient for publication of his medical findings.

Discussion

Hyperpneumatization of the cranial base bones is a rare condition. Temporal bone pneumatization begins during the last weeks of the pregnancy and continues till to end of the puberty (2). Mastoid process pneumatization is a normal condition, and its extension to the temporal squama is accepted as a normal variant (2). However extension of the pneumatization into the occipital, parietal and frontal bones and upper cervical vertebrae is a pathological condition and it is thought that it may be caused to habitual Valsalva maneuvers such as frequent nose blowing, or frequent positive pressure activities such as diving (5). Rebol et al. (2) reported a case with hyperpneumatization of the cranial base and calvarial bones extending to the parietal bones and they hypothesized that extension of the pneumatization through the sutures must be due to an etiologic factor developing before closure of the sutures. In the patient presented here, there was no risk factor. Zhao et al. (6) reported in a review consisting of 13 patients that there were not any risk factors to develop hyperpneumatization in 5 cases, such as to be in our case.

There were a few cases in literature with mastoid and occipital hyperpneumatization presenting with soft tissue swelling due to subcutaneous pneumatocele, or spontaneous CSF rhinorrhoea (3,6-10). There were fewer cases with hyperpneumatization of the upper cervical vertebrae presented with neck pain during neck movements (1,5,11,12). It is very rare, extension of hyperpneumatization into the parietal bones to reach the vertex. Rebol et al. (2) and Park et al. (4) reported such cases. The case reported by Park et al. (4) had presented with a severe headache due to a large epidural pneumatocele and he had been required surgical treatment. The case reported by Rebol et al. (2) had been diagnosed incidentally. The patient presented here was investigated for nonspecific chronic headache probably not related to this pathology. In addition, the patient had hyperpneumatization

of the atlas and free air around the atlantooccipital joint, but he had no neck pain spontaneously or during movements contradictory with other such cases reported in the literature (1,5,11,12). Rebol et al. (2) reported that hyperpneumatization may remain asymptomatic if the Eustachian tube is intact and functioning.

The hyperpneumatization of the cranial and upper cervical bones may cause some serious complications such as extracranial or intracranial pneumatocele, CSF fistula, or meningitis (2). In addition, intracranial or otologic operations in these patients are more risky for the development of postoperative CSF fistula, pneumocephalus or meningitis (8). Therefore, the asymptomatic patients must be aware of these complications and must be followed periodically. We followed our patient during 18 months after diagnosis and his neurologic condition was not change.

Conclusions

Hyperpneumatization of the cranial base and calvarial bones other than temporal bone and upper cervical vertebrae is a very rare condition. The patient may be asymptomatic or may be presented with minor complaints. If the condition is not associated with complications such as extracranial or intracranial pneumatocele, meningitis, or CSF fistula, the patients may be followed. However, they must be aware of possible complications.

Author contributions: Conception/Design of study - E.D.D., F.K.G., B.E., O.Y.A., E.O., G.V.; Data acquisition - E.D.D., E.O., G.V.; Data analysis/Interpretation - E.D.D., B.E., F.K.G.; Drafting manuscript - E.D.D., F.K.G., B.E., O.Y.A., E.O., G.V.; Critical revision of manuscript - E.D.D., F.K.G.; Final approval and accountability - E.D.D., F.K.G., B.E., O.Y.A., E.O., G.V.; Technical or material support - N/A; Supervision - F.K.G.

Informed Consent: Written informed consent was obtained from the patient.

Ethics Committee Approval: Ethics committee approval was not required for the case report.

Conflict of Interest: Authors declared no conflict of interest.

Financial Disclosure: Authors declared no financial support.

References

1. Al Felasi M, Venail F, Lonjon N. Spontaneous pneumarthrosis of the atlantoaxial joint. Case Report. *J Neurosurg Spine* 2012;16(1):27-30. [\[CrossRef\]](#)
2. Rebol J, Munda A, Tos M. Hyperpneumatization of the temporal, occipital and parietal bones. *Eur Arch Otorhinolaryngol* 2004;261(8):445-448. [\[CrossRef\]](#)
3. Zhang X, Jing M, Liang H, Meng X, Liu E, Zhao S. Traumatic subperiosteal emphysema caused by hyperpneumatization of the temporal and occipital bone. *J Neuroimaging* 2013;23(2):259-261. [\[CrossRef\]](#)
4. Park P, Chandler WF, Telian SA, Doran S. Spontaneous chronic epidural pneumocephalus resulting from hyperpneumatization of the cranium causing mass effect: Case report. *Neurosurgery* 1998;42(6):1384-6. [\[CrossRef\]](#)
5. Germino JC, Medvert JR, Nguyen VT, Favinger JL, Marder CP. Craniocervical hyperpneumatization with concurrent pneumorrhachis, pneumomediastinum, and subcutaneous emphysema in a weightlifter. *Spine J* 2013;13(10):e47-e53. [\[CrossRef\]](#)
6. Zhao N, Wang DD, Huang X, Karri SK, Wu H, Zheng M. Spontaneous otogenic pneumocephalus presenting with occipital subcutaneous emphysema as primary symptom: could tension gas cause the destruction of cranial bones? *J Neurosurg* 2011;115(4):679-683. [\[CrossRef\]](#)
7. Anorbe E, Aisa P, de Ormijana JS. Spontaneous pneumatocele and pneumocephalus associated with mastoid hyperpneumatization. *Eur J Radiol* 2000;36(3):158-160. [\[CrossRef\]](#)
8. Pettorini BL, Tamburrini G, Montano N, Massimi L, Caldarelli M, Paternoster G, et al. CSF otorrhea after anterior temporal craniotomy due to hyperpneumatization of the temporal bone. *Pediatr Neurosurg* 2008;44(2):176-177. [\[CrossRef\]](#)
9. Rivera D, Fermin-Delgado R, Stoeter P. "Spontaneous" CSF fistula due to transtegmental brain herniation in combination with signs of increased intracranial pressure and petrous bone hyperpneumatization: An illustrative case report. *J Neurol Surg Rep* 2014;75(2):e251-e254. [\[CrossRef\]](#)
10. Tucker A, Miyake H, Tsuji M, Ukita T, Nishihara K, Ito S, et al. Spontaneous epidural pneumocephalus-Case report. *Neurol Med Chir (Tokyo)* 2008;48(10):474-478. [\[CrossRef\]](#)
11. Littrell LA, Leutmer PH, Lane JJ, Driscoll CLW. Progressive calvarial and upper cervical pneumatization associated with habitual Valsalva maneuver in a 70-year-old man. *Am J Neuroradiol* 2004;25(3):491-493.
12. Rameh C, Meller R, Magnan J. Mastoid hyperpneumatization with atlantoaxial fistulization presenting as head rotation induced aural fullness. *Otol Neurotol* 2009;30(7):936-938. [\[CrossRef\]](#)