

# Cutaneous Metastasis from Squamous Cell Carcinoma of The Bladder: A Case

Huseyin Besiroglu<sup>1</sup>, Mustafa Erkok<sup>2</sup>, Suleyman Sahin<sup>3</sup>, Gulcin Kamali<sup>4</sup>, Alper Otunctemur<sup>5</sup>, Emin Ozbek<sup>6</sup>



## ABSTRACT

**Objective:** To report a case with cutaneous metastasis of bladder squamous cell carcinoma. Very few cases of skin metastases from the urinary bladder are reported in the literature.

**Case report:** Cutaneous metastasis of bladder squamous cell carcinoma is an extremely rare clinic entity associated with poor prognosis. Cutaneous metastasis is accepted as a late manifestation of systemic spread. A 58-year-old man had undergone radical cystoprostatectomy with pelvic lymph node dissection in November 2013. The pathology report showed a moderately differentiated squamous cell bladder carcinoma with a staging of T3N0M0. Then, a large regional cutaneous lesion measuring 4x3.5 cm with an ulcerated and necrotic appearance located in the suprapubic area was detected in February 2014, and the lesion was removed with a 2 cm safety margin. The pathologic examination revealed squamous cell carcinoma. This report describes an interesting and rare case of cutaneous metastasis of bladder squamous cell carcinoma as the primary presentation of metastatic disease with a generally dismal prognosis.

**Conclusion:** The skin metastasis of bladder squamous cell carcinoma is a rare clinical entity with a poor prognosis. Clinicians should be aware of this rare entity.

**Keywords:** bladder cancer, squamous cell carcinoma, metastasis

## ÖZET

**Mesanein skuamöz hücreli kanserinin cilt metastazı: Olgu sunumu**

**Giriş:** Mesanein skuamöz hücreli kanserinin cilt metastazı vakasını raporlamak amaçlanmıştır. Mesane kanserinin deri metastazı literatürde çok az vakada bildirilmiştir.

**Olgu sunumu:** Mesanein skuamöz hücreli kanserinin cilt metastazı çok nadir görülen ve kötü prognozla ilişkili bir klinik antitedir. Kutanöz metastaz sistemik yayılımın ileri safhalarındadır. Elli sekiz yaşındaki hastaya Kasım 2013'te radikal sistoprotektomi ve pelvik lenf nodu diseksiyonu uygulandı. Patoloji sonucu bize evresi T3N0M0 olan orta dereceli diferansiyasyonlu skuamöz mesane kanseri olduğunu gösterdi. Sonrasında Şubat 2014'te suprapubik alanda yer alan ülsere ve nekrotik görünümlü bir adet 4x3.5 cm büyüklüğünde geniş rejyonel kutanöz lezyon saptandı ve lezyon iki cm güvenilir sınırla çıkartıldı. Patoloji sonucu skuamöz hücreli karsinom geldi. Bu vaka mesanein skuamöz hücreli karsinomunda metastatik hastalıkla ilk olarak cilt metastazı görülmesi açısından çok nadir ve genel olarak kötü prognozlu bir olgudur.

**Sonuç:** Mesane kanserinin skuamöz hücreli karsinomunun deri metastazı kötü prognozlu ve nadir görülen klinik antitedir. Klinisyenler bu açıdan uyanık olmalıdır.

**Anahtar kelimeler:** mesane kanseri, metastaz, skuamöz hücreli karsinom

<sup>1</sup>Catalca Ilyas Cokay State Hospital, Department of Urology, Istanbul -Turkey

<sup>2</sup>Kanuni Sultan Suleyman Training and Research Hospital, Beylikduzu Campus, Department of Urology, Istanbul - Turkey

<sup>3</sup>Sisli Hamidiye Etfal Training and Research Hospital, Department of Urology, Istanbul-Turkey

<sup>4</sup>Okmeydani Training and Research Hospital, Department of Pathology, Istanbul-Turkey

<sup>5</sup>Okmeydani Training and Research Hospital, Department of Urology, Istanbul-Turkey

<sup>6</sup>Istanbul Training and Research Hospital, Department of Urology, Istanbul-Turkey

## Corresponding author:

Mustafa Erkok,  
Kanuni Sultan Suleyman Training and Research Hospital, Beylikduzu Campus, Department of Urology, Istanbul - Turkey

**E-mail address:** drmustafaerkoc@gmail.com

**Date of submission:** September 17, 2017

**Date of acceptance:** September 18, 2017

## Introduction

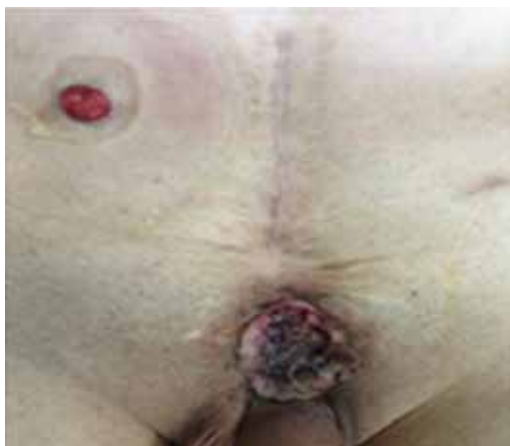Bladder cancer is the fourth most common cancer among men and the tenth most common cancer among women (1). Approximately 50% of patients will develop local recurrence and/or metastatic disease after radical cystectomy, whereas in 30% of the cases the tumor has invaded the bladder's muscle layer at the time of diagnosis (2). The most common metastatic

sites for bladder cancer are lymph nodes, liver, lung, and bone. The skin is an uncommon site of distant metastases (3). The overall incidence of cutaneous metastasis from primary solid visceral malignancies is 2.9% to 5.3%. The incidence of cutaneous metastasis from primary urinary malignancies is reported from 1.1% to 2.5%. The most common one is kidney cancer (3.4-4%) followed by urinary bladder cancer (0.84-3.6%) and prostate cancer (0.36-0.7%) (4). Cutaneous metastasis of

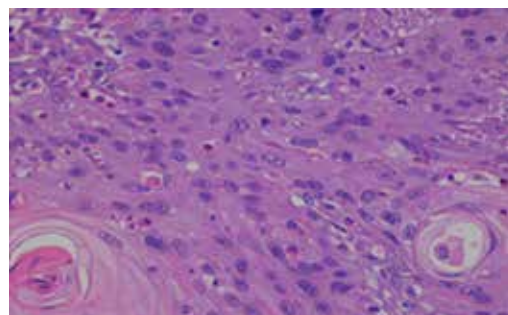
bladder cancer is a rare clinical entity. Very few cases of skin metastases from urinary bladder cancer are reported in the literature. The clinical presentation of cutaneous metastases varies and can mimic many types of skin diseases. The most common clinical pictures of cutaneous metastases from genitourinary malignancies are infiltrated plaques or nodules (5). We report a patient who presented with solitary ulcerated and necrotic metastasis from a squamous cell carcinoma of the bladder which was treated with local excision.

## Case presentation and management

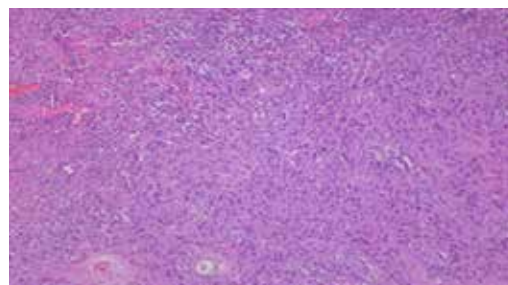
Informed consent was obtained from the patient. A 58-year-old healthy man presented to the outpatient clinic with a 2-month history of intermittent hematuria. A large tumoral lesion on the back wall of the bladder was revealed on cystoscopy. The patient had undergone transurethral resection of the bladder tumor with an incomplete resection. Histopathological examination had revealed muscle-invasive squamous cell carcinoma with a staging of T2N0M0. Metastatic workup including a chest X-ray and abdominal computerized tomography did not reveal distant metastases. We performed radical cystoprostatectomy and bilateral pelvic lymph node dissection in November 2013. Histopathological examination revealed a moderately differentiated squamous cell carcinoma with a staging of T3N0M0. Two months after radical cystoprostatectomy, the patient complained of extensive cutaneous lesion measuring 4x3.5 cm with an ulcerated and necrotic appearance located in the suprapubic area (Figure 1). The patient had no pain or tenderness. No



**Figure 1: The lesion extending from the termination of the previous incision line to the root of the penis.**



**Figure 2a: Malignant tumor with solid epithelial islands similar to stratified squamous epithelium.**



**Figure 2b: Malignant cells with large pleomorphic nuclei and cytoplasm similar to keratinocytes. The keratin pearls are also seen.**

fever or leukocytosis were noted. Magnetic resonance imaging scan of the pelvic area revealed that the lesion was limited to the cutaneous and subcutaneous fatty tissue, not extending to fascia and muscle tissue. There was no local invasion in the pelvic region. Since the performance of the patient was suitable, surgical treatment was administered. The lesion was totally removed leaving at least 2 cm of surgical safety margin to the tissue. The histopathology revealed that the lesion was squamous cell carcinoma with negative surgical margin. The demonstration of histopathologic examination is shown in Figures 2a and 2b.

## Discussion

Cutaneous metastasis from internal malignancies is a rare clinical entity and it may be the first sign of an advanced disease. The most common sites of metastatic disease from urologic malignancies include the lymph nodes, bones, liver, and lungs. Cutaneous involvement after urological malignancy is uncommon; the incidence of cutaneous metastasis from bladder malignancies ranges from 0.84% to 3.60%. Urologic cancers appear less likely to metastasize to the skin compared

with other primary malignancies; however, the incidence of either is low (5,6). There are a limited number of previously reported cases of bladder cancer with cutaneous metastasis. More than 90% of bladder carcinoma cases with cutaneous metastasis consist of transitional cell histopathology. To the best of our knowledge, this is the first case in the literature reporting skin metastasis of squamous cell carcinoma of the bladder.

There are four basic mechanisms of metastatic dissemination by which the skin may be accessed: (a) direct invasion from underlying neoplasm; (b) implantation from an operative scar; (c) spread through the lymphatics; and/or (d) hematogenous spread (7). In our report, the patient has a good performance status, and cutaneous metastasis developed in the absence of a widely metastatic disease. Cutaneous metastasis seems more likely to be a result of dissemination by cutaneous lymphatics or vessels. Cutaneous metastases often develop in the locoregional skin, usually abdomen, thighs and genitalia. The abdominal skin appears to be the most common metastatic cutaneous site (5). In our report, the metastatic site developed in the pubic region under the operative scar.

Cutaneous metastases are generally associated with carcinomas invading the bladder musculature or with a local advanced neoplasm, although the literature reports a few cases of cutaneous metastasis in early-stage bladder cancer (8). In our case, the histopathology of the cutaneous lesion revealed squamous cell carcinoma with negative surgery margin. The pathologic data were quite consistent with the initial diagnosis that this was a squamous cell carcinoma, but the primary origin was not clear. However, the pathologic stage of cystoprostatectomy was T3N0M0, indicating that the cutaneous lesion was a metastasis of bladder cancer. Furthermore, the cutaneous lesion emerged only two months after the radical cystoprostatectomy, which was a strong indicator demonstrating that the primary origin was in the bladder. Presence of cutaneous localization from urinary

bladder cancer is highly correlated to large metastatic disease (8). Conversely, the cutaneous lesion is the first sign of a metastatic disease. Metastatic workup did not reveal local invasion or distant metastases except the cutaneous metastatic lesion.

The prognosis of cancer cell metastasis to the skin is a poor outcome. Among patients with bladder cancer with cutaneous metastasis, the median survival is less than 12 months. However, very rare cases with extended survival have been reported (5). Local excision, radiotherapy, chemotherapy, immunological and combination therapy have been reported in previous studies (9). Due to the poor outcomes in these patients, the treatment options are limited and primarily supportive in nature.

In conclusion, we presented a quite rare case of cutaneous metastasis of squamous cell carcinoma, which became clinically evident 2 months after the initial radical treatment. The cutaneous lesion was the first sign of the metastatic disease. Metastatic disease should always be taken into account in patients with a previous history of bladder cancer who present with cutaneous lesion. Due to the advanced stage of the disease, in many cases the treatment is mainly supportive and prognosis is poor.

Contribution Categories	Name of Author
Follow up of the case	M.E., S.S., H.B., G.K., A.O.
Literature review	E.O., M.E., H.B., A.O., S.S.
Manuscript writing	E.O., G.K., H.B., S.S.
Manuscript review and revision	E.O., G.K., M.E., A.O.

**Ethics Committee Approval:** N/A.

**Informed Consent:** Written informed consent was obtained from the patient who participated in this study.

**Peer-review:** Externally peer-reviewed.

**Conflict of Interest:** Author declared no conflict of interest.

**Financial Disclosure:** Authors declared no financial support.

## References

- Jemal A, Siegel R, Ward E, Hao Y, Xu J, Thun MJ. Cancer statistics, 2009. *CA Cancer J Clin* 2009;59(4):225-249. [\[CrossRef\]](#)
- Vom Dorp F, Borgermann C, Rubben H. Palliative therapy concepts for patients with urothelial cancer of the urinary bladder. *Urologe A* 2007;46(1):54-55. [\[CrossRef\]](#)
- Saito S. Solitary cutaneous metastasis of superficial bladder cancer. *Urol Int* 1998;61(2):126-127. [\[CrossRef\]](#)
- Block CA, Dahmouh L, Konety BR. Cutaneous metastases from transitional cell carcinoma of the bladder. *Urology* 2006;67(4):846-848. [\[CrossRef\]](#)
- Mueller TJ, Wu H, Greenberg RE, Hudes G, Topham N, Lessin SR, et al. Cutaneous metastases from genitourinary malignancies. *Urology* 2004;63(6):1021-1026. [\[CrossRef\]](#)

6. Block CA, Dahmouh L, Konety BR. Cutaneous metastases from transitional cell carcinoma of the bladder. *Urology* 2006;67:15-17. [\[CrossRef\]](#)
7. Swick BL, Gordon JR. Superficially invasive transitional cell carcinoma of the bladder associated with distant cutaneous metastases. *J Cutan Pathol* 2010;37(12):1245-1250. [\[CrossRef\]](#)
8. Manzelli A, Quaresima S, Rossi P, Petrou A, Ricciardi E, Brennan N, et al. Solitary skin metastasis from sarcomatoid carcinoma of the bladder: a case report. *J Med Case Rep* 2011;5:484. [\[CrossRef\]](#)
9. Nshan D, Meiss F, Braun-Falco M, Reichenberger S. Cutaneous metastases from internal malignancies. *Dermatol Ther* 2010;23(6):567-80. [\[CrossRef\]](#)