

# Exophytic Giant Cell Glioblastoma in a Patient with Neurofibromatosis Type 1: Case Report

Meliha Gundag Papaker<sup>1</sup>, Serkan Kitis<sup>1</sup>, Mehmet Hakan Seyithanoglu<sup>1</sup>, Tolga Turan Dundar<sup>1</sup>, Zeynep Tosuner<sup>2</sup>



<sup>1</sup>Bezmialem Vakıf University, Faculty of Medicine, Department of Neurosurgery, Istanbul-Turkey  
<sup>2</sup>Bezmialem Vakıf University, Faculty of Medicine, Department of Pathology, Istanbul-Turkey

## Corresponding author:

Serkan Kitis,  
Bezmialem Vakıf University, Faculty of Medicine,  
Department of Neurosurgery, Istanbul-Turkey  
**Phone:** +90-212-453-1700  
**E-mail address:** serkankitis@yahoo.com

**Date of submission:** June 05, 2017

**Date of acceptance:** June 08, 2017

## ABSTRACT

Giant cell glioblastoma multiforme (GCGBM) is an uncommon subtype within the spectrum of glioblastoma multiforme (GBM) tumors. Neurofibromatosis type 1 (NF1) has an increased risk of developing neoplasms that generally are of a benign nature. We report a rare case of an exophytic GCGBM in a 43-year-old woman with NF1. The tumor located in the right frontal region was removed totally and the patient underwent radiotherapy with 60 Gy and chemotherapy with temozolomide.

**Keywords:** exophytic giant cell glioblastoma multiforme, neurofibromatosis Type 1, glioblastoma multiforme

## ÖZET

Nörofibromatozisli bir hastada ekzofitik dev hücreli glioblastoma tip 1: Olgu sunumu

Dev hücre glioblastoma multiforme (GCGBM), glioblastoma multiforme (GBM) tümör spektrumu içerisinde nadir görülen bir alt tiptir. Nörofibromatoz Tip 1 (NF1) genelde iyi huylu bir neoplazm gelişim riski taşır. NF1 olan 43 yaşındaki bir kadında nadir görülen bir ekzofitik GCGBM olgusunu sunuyoruz. Sağ frontal bölgede yer alan tümör tamamen çıkarıldı ve hastaya 60 Gy ile radyoterapi ve temozolomid ile kemoterapi uygulandı.

**Anahtar kelimeler:** ekzofitik dev hücre glioblastoma multiforme, nörofibromatoz Tip 1, glioblastoma multiforme

## Introduction

Giant cell glioblastoma multiforme (GCGBM) is a rare subtype of glioblastoma multiforme (GBM) tumors, occurring generally in the cerebral hemispheres. GCGBM predominantly occurs in younger patients and is more likely to allow for total resection. Consequently, compared with GBM, this tumor is associated with a better prognosis (1). Its magnetic resonance imaging (MRI) features, tumor size, and localization are similar to GBM except for its clear demarcations (2).

Few GCGBM cases with NF1 have been documented, such as GCGBM with bilateral cerebellopontine angle location in a patient with NF1 (3), GCGBM associated with NF1 in an 8-year-old patient (4), and exophytic GCGBM of the medulla oblongata (5).

## Case Presentation

A 43-year-old woman was admitted to our neurosurgery department with an MRI diagnosis of a large, right frontal tumor. She had multifocal subcutaneous neurofibromas and complained of headache. Her children have a peripheral type of NF1 with multiple small neurofibromas. The MRI showed a contrast-enhancing mass in the right frontal region. On the MRI, the tumor margin was well demarcated, while other margins were poorly demarcated (Figures 1,2). Right frontal craniotomy was performed. The tumor was totally resected.

On histopathological evaluation, the tumor showed the typical morphological features of glioblastoma such as palisading necrosis and high mitotic activity (13/10 HPF). Marked nuclear pleomorphism and bizarre nuclear features

were also evident. Besides, numerous giant multinuclear cells constituted the dominant component of the tumor. Immunohistochemical GFAP expression revealed the glial nature, and the final diagnosis was “giant cell glioblastoma” (Figure 3).

After discharge from the hospital, the patient underwent both radiotherapy with an overdose of 60 Gy over a period of 6 weeks and chemotherapy. The patient had an excellent outcome after tumor excision and radiochemotherapy. Five months later, the MRI showed regression of the tumor (Figure 4).

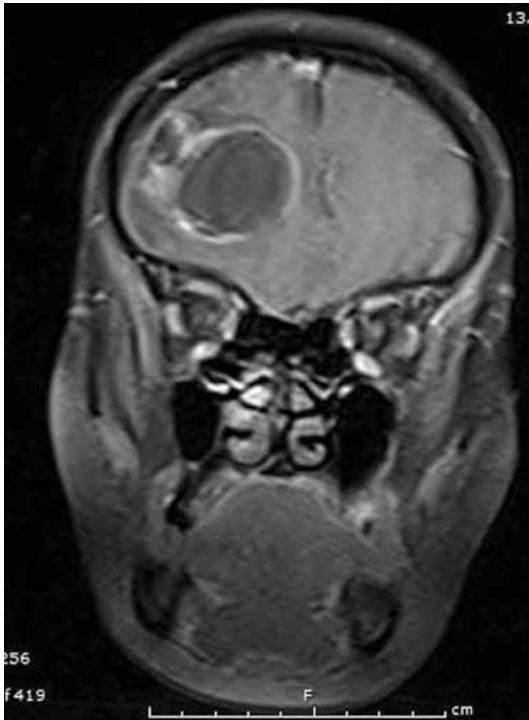


Figure 1: T1- weighted coronal MRI scan of the brain (after i.v. gadolinium administration). T1- weighted coronal MRI showed a lesion in the right frontal lobe.

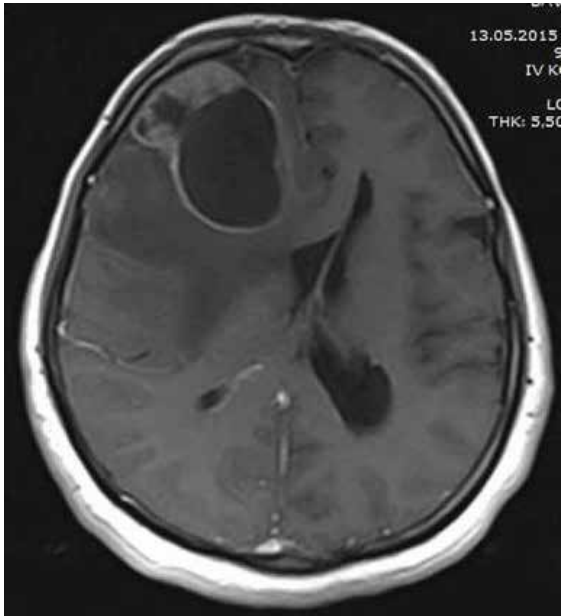


Figure 2: T1- weighted axial MRI scan of the brain (after i.v. gadolinium administration). T1- weighted axial MRI showed a lesion in the right frontal lobe.

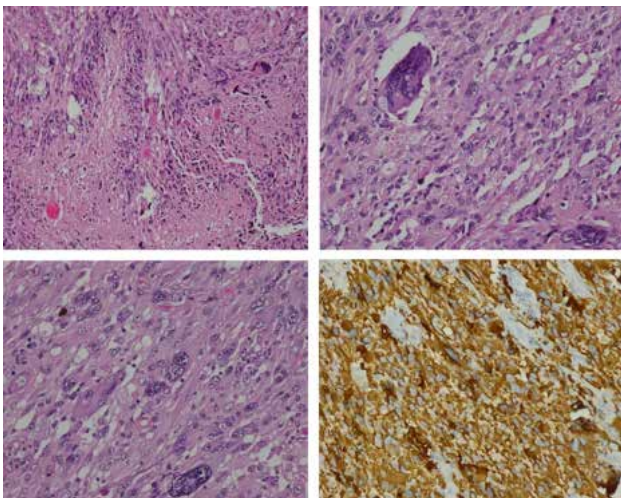


Figure 3: Histopathological and immunohistochemical findings.

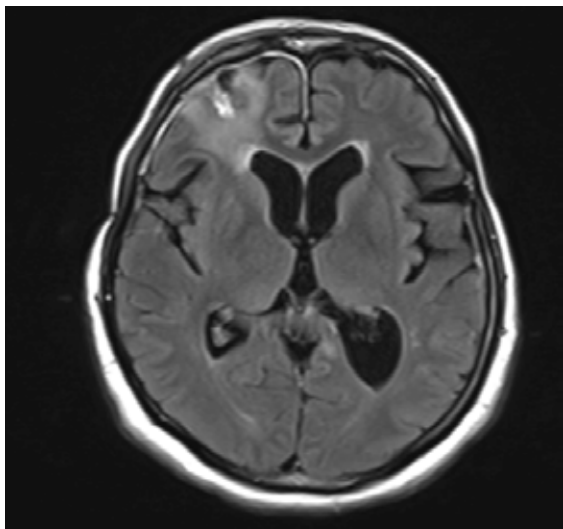


Figure 4: Axial image enhanced with gadolinium obtained at the 5-months follow-up show linear contrast enhancement in the right frontal lobe.

## Discussion

Neurofibromatosis type 1 is the most common neurocutaneous disease with a prevalence of approximately 1 in 2600 to 1 in 3000 individuals and one of the most prevalent genetic diseases of the nervous system (6). The most common central nervous system (CNS) tumors are gliomas, especially in children, and generally involve the optic pathways (7). In addition, brain tumors, pheochromocytomas, and leukemias occur in NF1 patients with increased frequency (8).

GBM is the most malignant primary cerebral tumor and accounts for 50% of all gliomas in adults. GCGBM is a variant of GBM and accounts for 5% of all GBMs and 1% of primary brain tumors (9). Although GCGBM is associated with better prognosis and long-term survival of the patients, some GCGBM cases with fatal outcome and short survival time have also been reported (10). Our patient presented in this report ameliorated after a combination of surgery and radiochemotherapy.

To our knowledge, few reports of GCGBM cases are

associated with NF1 patients. GCGBM with bilateral cerebellopontine angle location in a patient with NF1, GCGBM associated with NF1 in an 8-year-old patient, and exophytic GCGBM of the medulla oblongata have been reported (3-5). We report an exophytic GCGBM in the right frontal region in a patient with NF1.

It is important to differentiate GCGBM from the other high-grade tumors, subependymal giant cell astrocytoma, pleomorphic xanthoastrocytoma and metastasis, because it may have a better prognosis and longer-time survival.

Contribution Categories	Name of Author
Follow up of the case	M.G.P., S.K., M.H.S., T.T.D.
Literature review	M.G.P., M.H.S., Z.T.
Manuscript writing	M.G.P., S.K., T.T.D., Z.T.
Manuscript review and revision	S.K., M.H.S., T.T.D., Z.T.

**Conflict of Interest:** Authors declared no conflict of interest.

**Financial Disclosure:** Authors declared no financial support.

## References

- Kozak KR, Moody JS. Giant cell glioblastoma: A glioblastoma subtype with distinct epidemiology and superior prognosis. *Neuro Oncol* 2009;11(6):833-841. [\[CrossRef\]](#)
- Karremann M, Butenhoff S, Rausche U, Pietsch T, Wolff JE, Kramm CM. Pediatric giant cell glioblastoma: New insights into a rare tumor entity. *Neuro Oncol* 2009;11(3):323-329. [\[CrossRef\]](#)
- Taraszevska A, Bogucki J, Powala A, Matyja E. Giant cell glioblastoma with unique bilateral cerebellopontine angle localization considered as extraaxial tumor growth in a patient with neurofibromatosis Type 1. *Clin Neuropathol* 2013;32(1):58-65.
- Kroh H, Matyja E, Marchel A, Bojarski P. Heavily lipidized, calcified giant cell glioblastoma in an 8-year-old patient, associated with neurofibromatosis type 1(NF1): report of a case with long-term survival. *Clin Neuropathol* 2004;23(6):286-291.
- Luetjens G, Mirzayan MJ, Brandis A, Krauss JK. Exophytic giant cell glioblastoma of the medulla oblongata. *J Neurosurg* 2009;110(3):589-593. [\[CrossRef\]](#)
- Lammert M, Friedman JM, Kluwe L, Mautner VF. Prevalence of neurofibromatosis 1 in German children at elementary school enrollment. *Arch Dermatol* 2005;141(1):71-74. [\[CrossRef\]](#)
- Rodriguez FJ, Perry A, Gutmann DH, O'Neill BP, Leonard J, Bryant S, et al. Gliomas in neurofibromatosis type 1: A clinicopathologic study of 100 patients. *J Neuropathol Exp Neurol* 2008;67(3):240-249. [\[CrossRef\]](#)
- Korf BR. Malignancy in neurofibromatosis type 1. *Oncologist* 2000;5(6):477-485. [\[CrossRef\]](#)
- Kleihues P, Burger PC, Aldape KD, et al. Glioblastoma. In: Louis DN, Ohgaki H, Wiestler OD, Cavenee WK (eds). *WHO Classification of tumours of the Central Nervous System*. Lyon: IARC Press; 2007. p. 33-49.
- Valle-Folgueral JM, Mascarenhas L, Costa JA, Vieira F, Soares-Fernandes J, Belezza P, et al. Giant cell glioblastoma: review of the literature and illustrated case. *Neurocirugia (Astur)*. 2008;19(4):343-349. [\[CrossRef\]](#)