

# First Transapical Aortic Valve Replacement at Bagcilar Training and Research Hospital

Nihan Kayalar<sup>1</sup>, Kamil Boyacioglu<sup>1</sup>, Serkan Ketenciler<sup>1</sup>, Ibrahim Yildizhan<sup>1</sup>, Vedat Erentug<sup>1</sup>



## ABSTRACT

Transcatheter-based aortic valve procedures have undergone a tremendous evolution and have led to great changes in the treatment of aortic valvular disease. In patients with severe peripheral arterial disease, transapical aortic valve implantation is an important alternative to surgical aortic valve replacement. Hereby we present our first case of transapical aortic valve implantation in an 80 year-old patient.

An 80-year old female patient applied with dyspnea on minimal exertion (NYHA Class III). Transthoracic echocardiography showed severe aortic stenosis (gradients of 76/45 mmHg, aortic valve area of 0.72 cm<sup>2</sup>). Patient had a history of coronary artery bypass grafting and chronic obstructive pulmonary disease. Calculated Euroscore was 16.4% and due to the high surgical risk and presence of diffuse vascular disease, transapical aortic valve implantation was decided to be the optimal choice for the patient. The procedure was performed in the catheter laboratory under general anesthesia via a 5-6 cm anterolateral thoracotomy and via transapical approach. Fluoroscopy was used to guide the catheter across the native valve and direct deployment of the stent at the level of the annulus. A 26 mm Edwards Novoflex (Edwards Lifesciences, Irvine, CA) aortic valve was used. Postoperative echocardiography showed no transvalvular gradient and aortic regurgitation. Aorta flow was 1.1 m/s.

Transcatheter-based aortic valve procedures avoid the risks associated with open heart surgery and therefore are generally indicated in patients with high surgical risk. Although TAVI is the first alternative to SAVR in high risk patients, TA-TAVI is a safe and effective option in those unsuitable for TAVI.

**Keywords:** aortic valve, transfemoral aortic valve replacement, transapical aortic valve replacement

## ÖZET

Bağcılar Eğitim ve Araştırma Hastanesi'nde ilk transapikal aort kapak replasmanı Transkateter aort kapak prosedürleri büyük bir ilerleme göstermiş ve aort kapak hastalıkları tedavisinde değişikliklere yol açmıştır. Ciddi periferik arter hastalığı olanlarda transapikal aort kapak replasmanı cerrahi kapak replasmanına önemli bir alternatif oluşturmaktadır. Burada 80 yaşında bir hastada uyguladığımız ilk transapikal kapak replasmanı vakamızı sunmaktayız.

Seksen yaşında bayan hasta hafif eforla dispne (NYHA Class III) şikayetiyle başvurdu. Transtorasik ekokardiyografide ciddi aort stenozu (gradient: 76/45 mmHg, aort kapak alanı: 0.72 cm<sup>2</sup>) belirlendi. Hastanın koroner bypass cerrahisi ve kronik akciğer hastalığı hikayesi mevcuttu. Hesaplanan Euroscore değeri %16.4'tü ve yüksek cerrahi risk ve yaygın vasküler hastalık nedeniyle en iyi seçeneğin transapikal kapak replasmanı olduğuna karar verildi. İşlem kateter laboratuvarında, genel anestezi altında, 5-6 cm anterolateral torakotomi ile transapikal olarak gerçekleştirildi. Kateterin nativ kapaktan geçirilmesi ve kapağın anulus seviyesinde açılması fuloroskopi rehberliğinde yapıldı. 26 mm Edwards Novoflex (Edwards Lifesciences, Irvine, CA) aort kapak kullanıldı. Postoperatif ekokardiyografide transvalvuler gradient ve aort kapak yetersizliği yoktu. Aort akımı 1.1 m/s idi.

Transkateter aort kapak prosedürleri açık kalp cerrahisinin risklerinden kaçınmayı sağlamakta ve bu nedenle genellikle cerrahi riski yüksek hastalarda tercih edilmektedir. Transfemoral kapak replasmanı, riski yüksek hastalarda cerrahi kapak replasmanına ilk alternatif olmakla birlikte, bu işlem için uygun olmayan hastalarda transapikal kapak replasmanı güvenli ve etkili bir alternatiftir.

**Anahtar kelimeler:** aort kapak, transfemoral aort kapak replasmanı, transapikal aort kapak replasmanı

<sup>1</sup>Bagcilar Research and Training Hospital, Cardiovascular Surgery Department, Istanbul, Turkey

## Corresponding author:

Nihan Kayalar,  
Bagcilar Training and Research Hospital,  
Cardiovascular Surgery Department,  
Merkez Mahallesi, 6. Sok. 34200 Bagcilar,  
Istanbul, Turkey  
**Phone:** +90-212-440-4000  
**Fax:** +90-212-440-4242  
**E-mail address:** nkayalar@hotmail.com

**Date of submission:** November 8, 2016

**Date of acceptance:** November 12, 2016

## Introduction

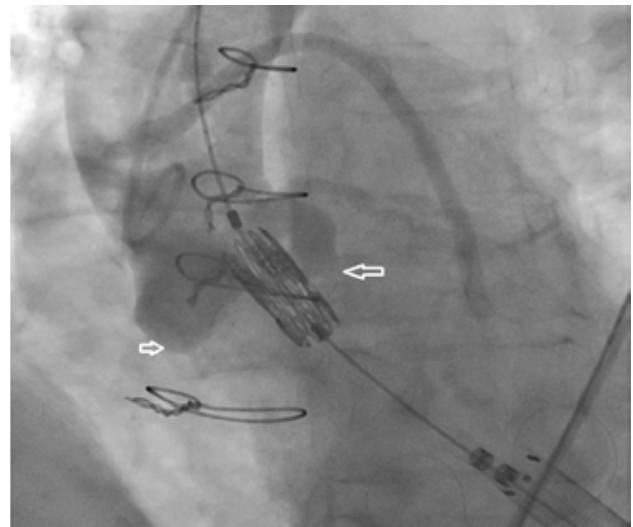
Transcatheter aortic valve implantation (TAVI) is an increasingly popular alternative to surgical aortic valve replacement (SAVR). Nevertheless, in patients with severe peripheral arterial disease that precludes vascular access, it may not be possible to perform a TAVI. Transapical transcatheter-based aortic valve implantation (TA-TAVI) has been reported to be a safe and efficient alternative to classic surgery, especially in high-risk patients (1). Since this approach is minimally invasive and eliminates the need of sternotomy and cardiopulmonary bypass (CPB), it can be used as an alternative to SAVR and TAVI in patients with high surgical risk and with diffuse vascular disease. Hereby we present our first case of TA-TAVI in an 80-year-old patient with severely stenotic abdominal aorta and iliac disease.

## Case

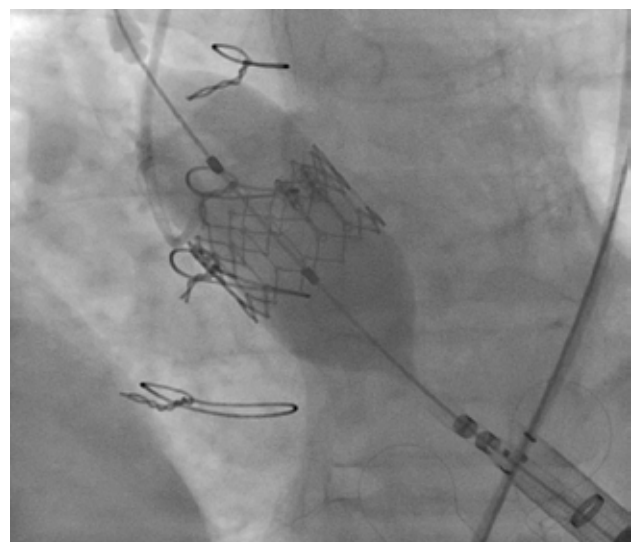
An 80-year-old female patient presented with dyspnea on minimal exertion (NYHA Class III) which had started a few months back. Transthoracic echocardiography showed severe aortic stenosis with maximum/mean transaortic gradients of 76/45 mmHg, aortic valve area was 0.72 cm<sup>2</sup>, left ventricular ejection fraction was 45%, and systolic pulmonary artery pressure was 36 mmHg. The patient had a history of 3-vessel coronary artery bypass grafting surgery 10 years ago and chronic obstructive pulmonary disease. Coronary angiography revealed patent coronary bypass grafts. Calculated Euroscore was 16.4%, and due to the high surgical risk, TAVI was planned. However, severe stenosis of the infrarenal abdominal aorta and

diffuse atherosclerotic iliac disease was seen on computed tomography angiography (Figure 1). Ascending aorta and arcus were also calcified preventing transaortic approach. TA-TAVI was decided to be the optimal choice for the patient.

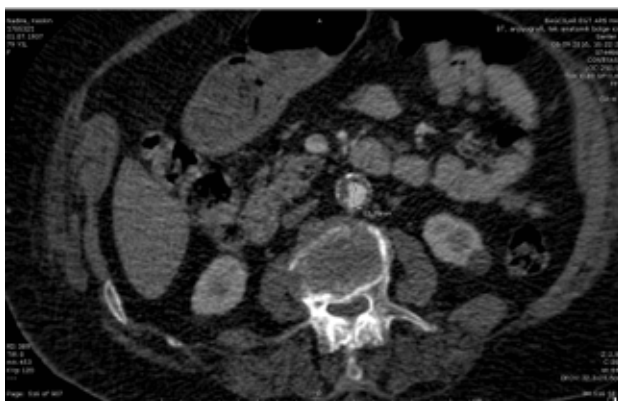
The procedure was performed in the catheter laboratory under general anesthesia via a 5-6 cm anterolateral thoracotomy in the fifth intercostal space to access the apex of the heart. A bipolar epicardial pacing wire was placed and tested. Two purse stitches with Teflon felt pledgets using 3-0



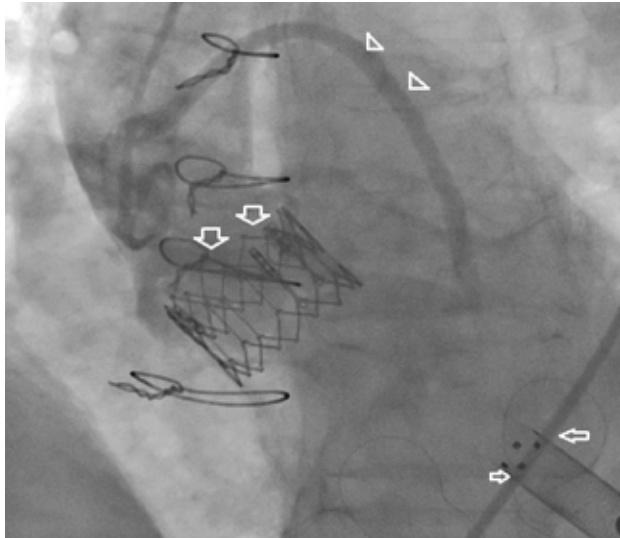
**Figure 2: Fluoroscopic image showing the catheter across the native valve. Arrows show the level of the aortic annulus.**



**Figure 3: Valve deployment with standard volumetric inflation of the balloon.**



**Figure 1: Preoperative CT angiography showing severe stenosis of infrarenal abdominal aorta.**



**Figure 4: Assessment of valve function by angiographic visualization. Arrowheads show patent saphenous vein graft, large arrows show deployed aortic valve and small arrows show the catheter through the apex of the heart.**

Prolene polypropylene were placed in the apex of the left ventricle. Fluoroscopy was used to guide the catheter across the native valve and direct deployment of the stent at the level of the annulus (Figure 2). Following balloon valvuloplasty, valve deployment was performed with standard volumetric inflation of the balloon (Figure 3). During balloon valvuloplasty and deployment, the heart was unloaded with rapid ventricular pacing. A 26 mm Edwards Novoflex (Edwards Lifesciences, Irvine, CA) aortic valve was used. Valve function was immediately assessed by angiographic visualization (Figure 4). A left lateral chest tube was inserted. The incision was closed in a standard fashion. Postoperative echocardiography showed no transvalvular gradient and aortic regurgitation. Aorta flow was 1.1 m/s. The patient was discharged on the 7<sup>th</sup> postoperative day without any major complications.

## Discussion

Transcatheter-based aortic valve procedures have undergone tremendous evolution during the past decade and have led to great changes in the treatment of valvular heart disease (2). Although being suitable primarily for patients with aortic stenosis, with the development of a specific ‘clipping-mechanism’ for fixation of aortic valve cusps, it has also been used in patients with pure aortic regurgitation. These

procedures help to avoid the risks associated with open-heart surgery and are therefore generally indicated in patients with high surgical risk, with a history of previous cardiac surgery and with multiple comorbidities. In our patient, main reasons for choosing a catheter-based procedure were previous coronary artery bypass grafting, chronic obstructive pulmonary disease, reduced ejection fraction, advanced age, and poor mobility of the patient before the operation.

Main advantages of transcatheter-based aortic valve procedures are the avoidance of sternotomy and cardiopulmonary bypass along with the associated potential risks. In addition, TAVI can be done under local anesthesia in certain cases. Although patients selected for TAVI have a higher surgical risk, comorbidities, and are in old age, they were reported to experience better in-hospital recovery and similar short- and mid-term mortality compared to those who underwent surgical aortic valve replacement (3). Moreover, TAVI enables early rehabilitation and discharge. The event rates for periprocedural stroke, MI, tamponade, major vascular complications, and in-hospital mortality were all reported to be low (4). On the other hand, TAVI is associated with an increased risk of experiencing symptoms of heart failure by about, permanent pacemaker insertion, and aortic valve reintervention in the short term (5). Post-TAVI conduction abnormalities result primarily from mechanical compression of the specialized adjacent conduction system by the device. Despite these risks associated with TAVI, its advantages have made this procedure the first alternative in inoperable and high-risk patients.

When compared, transfemoral TAVI results in better outcomes relative to SAVR than the transapical approach relative to SAVR; this is true for mortality, stroke, acute kidney injury, and bleeding (5). TA-TAVI shares benefits of less bleeding, less atrial fibrillation, and shorter hospital stay but increases the risk of stroke compared with SAVR and can also increase mortality (5). Nevertheless, TAVI requires a transfemoral, direct aortic or sometimes an upper extremity approach for insertion. In the presence of poor vascular access, as in the case of severe aortic and iliac atherosclerosis, small caliber of arteries and severe calcification of aorta, TA-TAVI is an effective alternative to TAVI. In our patient, due to the high surgical risk a TAVI was planned initially. Since the preoperative assessment revealed severe peripheral arterial disease along with heavily calcified ascending aorta and arch, TA-TAVI was

decided to be more suitable. Although TAVI is the first alternative to SAVR in high-risk patients, TA-TAVI is a safe and effective option for those unsuitable for TAVI.

## Conclusion

Transcatheter-based aortic valve procedures avoid the risks associated with open-heart surgery and therefore are generally indicated in patients with high surgical risk. Their main advantages are the avoidance of sternotomy and cardiopulmonary bypass along with the associated potential risks. Although TAVI is the first alternative to SAVR in

high-risk patients, TA-TAVI is a safe and effective option for those unsuitable for TAVI.

Contribution Categories	Name of Author
Follow up of the case	N.K., B.K., S.K.
Literature review	N.K., V.E., S.K., I.Y.
Manuscript writing	N.K., B.K., V.E., I.Y.
Manuscript review and revision	N.K., B.K., V.E., S.K., I.Y.

**Conflict of Interest:** Author declared no conflict of interest.

**Financial Disclosure:** Authors declared no financial support.

## References

- Papadopoulos N, El-Sayed Ahmad A, Thudt M, Fichtlscherer S, Meybohm P, Reyher C, et al. Successful fast track protocol implementation for patients undergoing transapical transcatheter aortic valve implantation. *J Cardiothorac Surg* 2016;11(1):55-62. [\[CrossRef\]](#)
- Papadopoulos N, Wenzel R, Thudt M, Doss M, Wimmer-Greinecker G, Seeger F, et al. A Decade of Transapical Aortic Valve Implantation. *Ann Thorac Surg* 2016;102(3):759-65. [\[CrossRef\]](#)
- Alsara O, Alsarah A, Laird-Fick H. Advanced age and the clinical outcomes of transcatheter aortic valve implantation. *J Geriatr Cardiol* 2014;11(2):163-170.
- Landes U, Barsheshet A, Finkelstein A, Guetta V, Assali A, Halkin A, et al. Temporal trends in transcatheter aortic valve implantation, 2008-2014: patient characteristics, procedural issues, and clinical outcome. *Clin Cardiol* 2016 Oct;1-7. [\[CrossRef\]](#)
- Siemieniuk RA, Agoritsas T, Manja V, Devji T, Chang Y, Bala MM, Thabane L, Guyatt GH. Transcatheter versus surgical aortic valve replacement in patients with severe aortic stenosis at low and intermediate risk: systematic review and meta-analysis. *BMJ*. 2016;28;354-63. [\[CrossRef\]](#)