

Late Surgical Treatment of Iatrogenic Femoral Vein Ligation During Open Inguinal Hernia Repair

Serkan Ketenciler¹, Kamil Boyacioglu¹, Ilknur Akdemir¹, Vedat Erentug¹, Nihan Kayalar¹



ABSTRACT

Vascular complications during inguinal hernia repair are rarely seen; however, iliac vein ligation may be performed by the inexperienced surgeon. Here, we present a case of iatrogenic external iliac vein ligation diagnosed and surgically treated about one day after surgery.

A 58-year-old male patient with bilateral inguinal hernia underwent open bilateral inguinal hernia repair. On the first postoperative day, severe edema, increased warmth and pain of the right leg developed. Duplex ultrasonography (USG) examination of the right lower extremity revealed acute thrombosis of deep veins. The patient was taken to vascular surgery about 24 hours after the inguinal hernia repair operation. It was detected that the right external iliac vein had been ligated iatrogenically during the initial operation. It was repaired with a duplicated saphenous vein patch.

The diameter of the right leg decreased dramatically early after operation. The patient was discharged on the 3rd day postoperatively. On follow-up, the patient's complaints regressed dramatically; we did not observe any complications and at six months, computerized tomography venography showed absence of stenosis of iliac vein.

Major vascular complications after inguinal hernia repair operations must be kept in mind because of close proximity of the surgical area to main vascular structures. The surgical treatment of deep vein thrombosis after ligation of the iliac vein provides an efficient and quick repair if proper surgical techniques are used.

Keywords: Deep vein thrombosis, saphenous patchplasty, surgery, inguinal hernia repair

ÖZET

Açık inguinal tamir operasyonu esnasında iyatrojenik femoral ven ligasyonununun geç dönem cerrahi tedavisi

İnguinal herni operasyonlarında vasküler komplikasyonlar nadir olarak görülür. Az tecrübeli bir cerrah tarafından iliak ven iyatrojenik olarak ligate edilebilir. Bu vaka sunumunda, herni tamiri sonrası tespit edilen iliak ven ligasyonunu ve cerrahi tedavisini paylaştık.

Elli sekiz yaşında erkek hastanın bilateral inguinal herni sebebiyle opere edildikten sonra, postoperatif 1. gününde sağ bacağına ciddi şişlik, ısı artışı ve ağrı meydana gelmiş. Sağ alt ekstremiteye yönelik yapılan dupleks venöz ultrasonografide derin ven trombozu saptandı. Hasta ameliyatından 24 saat sonra derin ven trombozu tanısıyla operasyona alındı. İntraoperatif eksplorasyonda sağ iliak venin iyatrojenik olarak ligate olduğu görüldü. İliak ven duplike safen yama ile tamir edildi.

Vasküler operasyondan kısa bir süre sonra hastanın sağ bacağına ciddi bir çap azalması saptandı ve ağrısı tamamen geçti. Hasta postoperatif 3. günde sorunsuz taburcu edildi. Takibinde, hastanın şikayetleri tamamen geçti, 6. ay kontrolünde yapılan bilgisayarlı tomografik venografide iliak venin açık olduğu ve darlık olmadığı görüldü.

İnguinal herni operasyonlarında iliak damarların yakınlığından dolayı major vasküler komplikasyonlar mutlaka akılda tutulmalıdır. İliak venin ligasyonuna bağlı oluşan derin ven trombozunun cerrahi tedavisi, doğru teknikler kullanılırsa oldukça efektif ve hızlı iyileşme sağlamaktadır.

Anahtar kelimeler: Derin ven trombozu, inguinal herni tamiri, safen yama, cerrahi

¹Bagcilar Research and Training Hospital, Cardiovascular Surgery Department, Istanbul, Turkey

Corresponding author:

Serkan Ketenciler,
Bagcilar Research and Training Hospital,
Cardiovascular Surgery Department,
Merkez Mahallesi, 6. Sokak, Bagcilar 34200
Istanbul, Turkey
Phone: +90-212-440-4000
Fax: +90-212-440-4242
E-mail address: ketencilers@hotmail.com

Date of submission: October 24, 2016

Date of acceptance: November 7, 2016

Introduction

Open or laparoscopic inguinal hernia repair is a frequently performed procedure in general surgery clinics. Complication

rate for this procedure is about 7-12%, including regional hematoma, scrotal hematoma, vas deferens injury, regional nerve injury, vascular injury, deep vein thrombosis, and entrapment of vessels (1). Intraoperative iliac artery or vein

injury presents an emergency situation which, if diagnosed quickly, can be repaired during the same operation. The ligation of iliac veins may be performed rarely by the inexperienced surgeon if mistaken for a side branch. In this case, the diagnosis may be delayed until relevant symptoms such as swelling of the leg or pain develop. Here, we present a case of iatrogenic external iliac vein ligation diagnosed about one day after surgery that was successfully treated by iliac vein reconstruction.

Case

A 58-year-old male patient with bilateral inguinal hernia underwent open bilateral inguinal hernia repair. On the first postoperative day, severe edema, increased warmth and pain of the right leg developed. Therefore, the patient was referred to our clinic for assessment of a suspected vascular complication due to the ligation of a large vein during inguinal hernia repair. Duplex ultrasonography (USG) examination of the right lower extremity revealed acute thrombosis of deep veins throughout the leg starting from the external iliac vein. The patient was taken to vascular surgery about 24 hours after the inguinal hernia repair operation. The right external iliac vein was explored via vertical groin incision, and it was detected that the vein had been ligated iatrogenically during the initial operation and deep veins distal to that level were thrombosed. Proximal and distal ligated ends of the external iliac vein were identified and sutures were untied to see if an end-to-end repair would be possible. After systemic heparinization, the thrombus in the immediate vicinity of the ligated site was extirpated. The proximal site of the vein was cleared easily in this way and a good backflow was observed. A bulldog clamp was applied to the proximal site for control of this flow. It was not possible to send a Fogarty catheter to the distal part due to the valves, and in order to avoid any damage to these valves, we applied repeated compressions to the leg starting from the most distal part. The distal thrombus bulk was cleaned mechanically in this way and a good amount of thrombus was extirpated. This was performed repeatedly until no more thrombus cleared from the distal part and a good backflow was obtained. After placement of a bulldog clamp to the distal vein, it was decided that the vein defect was too large to allow primary repair. A saphenous vein taken from the other extremity was longitudinally augmented to increase the size and was used to repair the external iliac vein as a patchplasty (Figure 1). The diameter of the right leg

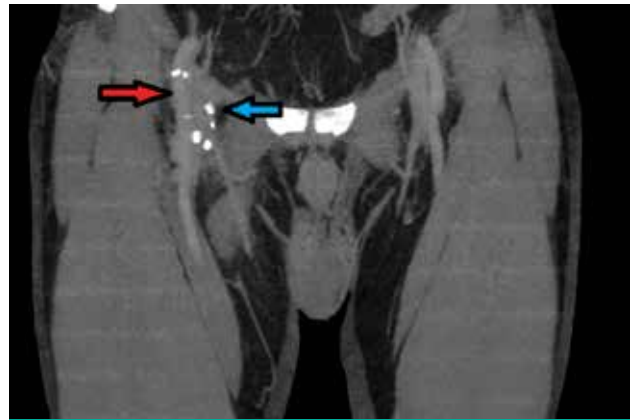


Figure 1: External iliac vein patchplasty with saphenous vein (Blue arrow), external iliac artery (Red arrow)

decreased dramatically early after operation. Anticoagulation treatment was started immediately after operation, and no new deep vein thrombosis or pulmonary embolism were observed during hospital follow-up. The patient was discharged on the 3rd postoperative day.

Discussion

Iliac vessel injury or entrapment is one of the most serious complications that can be seen after inguinal hernia repair operations; only a few cases have been reported in the literature (2). Normington et al. (3) mentioned that the femoral vein was easily constricted during McVay herniorrhaphy. They presented a case of femoral vein constriction caused by McVay herniorrhaphy that was diagnosed by venous duplex USG, which they recommended as an excellent noninvasive radiological method to evaluate possible femoral vein constriction after herniorrhaphy. We also believe that the Doppler USG is an easy noninvasive method for diagnosis of lower extremity venous disorders and should be the initial diagnostic tool of choice. In patients such as ours with iatrogenic injuries after hernia operations, since the localization of venous lesion is usually around the inguinal hernia operation incision, it can be used as the sole diagnostic technique. In our patient, venous duplex USG was performed for diagnosis, showing acute deep vein thrombosis of the right lower extremity, and the decision for operation was based on this technique. When there is doubt about the site of injury, venography can be used to determine the exact location of venous pathology and to plan the operative strategy. Bjorgul et al. (4) also discussed the same

situation, but they pointed out that the clinical presentation of this situation could even be pulmonary embolism and venography was important for diagnosis. Popovic et al. (5) presented a case report where iatrogenic injury of the femoral vein during inguinal herniorrhaphy operation was repaired with saphenous vein graft patchplasty.

These vascular complications after inguinal hernia repair can present as thrombosis of iliac and distal major venous vessels, and pulmonary embolism can occur as a complication of deep vein thrombosis because of entrapment of the iliac vein. Iliac vein thrombosis can be managed medically, interventional, or surgically. Anticoagulant drugs are preferred for medical treatment of deep venous thrombosis, usually including fractional or unfractional heparin and vitamin K-dependent anticoagulants. Interventional treatment options are catheter-based thrombolysis, pharmacomechanical methods and rheolytic thrombectomy.

The use of surgery for thrombosis is controversial. In the past, venous thrombectomy was a more acceptable and applicable method, but improvements in nonsurgical treatment modalities for deep vein thrombosis led to a decreased use of surgical thrombectomy. However, surgical treatment can be considered if entrapment or blockage of the iliac vein occurs. In our case, since the iliac vein occlusion was iatrogenic, there was no way of reconstructing anatomic continuity other than surgery. In the literature, the timing of surgical intervention is not clearly defined. However, if there is no option other than surgery, it is reasonable not to delay the intervention. In our case, there was severe swelling of the leg and intractable pain unresponsive to medical treatment. Therefore, we decided to operate urgently, and the iliac vein was successfully reconstructed with saphenous vein graft patchplasty. Due to the size of the external iliac vein, the diameter of the saphenous vein is usually not sufficient to reconstruct that vessel. For this reason, the size of the saphenous vein should be augmented or alternatively a prosthetic vascular graft can be used. The risk of

thrombosis is higher for prosthetic grafts under low-flow conditions of venous vessels; therefore, we preferred an augmented saphenous vein graft for this position. Another important technical aspect of the operation is the extirpation of thrombus from the extremity as much as possible. Thrombectomy localized only in the injured segment of the vein will leave a large thrombus load distal to the affected area. The “milking” of the leg with compressions from distal to proximal can extirpate most of the thrombus in these vessels as in our case. Moreover, this decreases the risk of pulmonary embolism after reconstructing anatomic continuity of the vein. Early institution of anticoagulant treatment also helps to prevent this complication. On follow-up, patient’s complaints regressed dramatically; we did not observe any complications and at six months, computerized tomography venography showed absence of stenosis of the iliac vein.

Conclusion

Major vascular complications after inguinal hernia repair operations must be kept in mind because of the close proximity of the surgical area to main vascular structures. Early diagnosis of these vascular complications, either arterial or venous, is of great importance for morbidity and mortality of the patient. The surgical treatment of deep vein thrombosis after ligation of the iliac vein provides an efficient and quick repair if proper surgical techniques are used.

Contribution Categories	Name of Author
Follow up of the case	S.K., N.K., I.A., V.E.
Literature review	S.K., K.B., I.A.
Manuscript writing	S.K., N.K., V.E., K.B.
Manuscript review and revision	N.K., V.E., I.A., K.B.

Conflict of Interest: Author declared no conflict of interest.

Financial Disclosure: Authors declared no financial support.

References

- Gaines RD. Complications of groin hernia repair: Their prevention and management. *J Natl Med Assoc* 1978;70(3):195-198.
- Aghaji MA, Ojimba TA. Life threatening iatrogenic major vascular injuries complicating groin hernia repair. *West Afr J Med* 1992;12(2):133-135.
- Normington EY, Franklin DP, Brotman SI. Constriction of the femoral vein after McVay inguinal hernia repair. *Surgery* 1992;111(3):343-7.
- Bjørgul K, Forsell C, Andersen OK. Constriction of the femoral vein after McVay hernioplasty [Norwegian]. *Tidsskr Nor Laegeforen* 1994;114(21):2489-90.
- Popovic J, Hut'an M. Injury of the femoral vein – a complication in inguinal hernia surgery [Slovak]. *Rozhl Chir* 1996;75(1):8-10.