

# Comparing The Rate of Radiological and Clinical Adjacent Segment Degeneration After Simple Anterior Cervical Discectomy Versus Discectomy Plus Fusion

Ozgur Yusuf Aktas<sup>1</sup>, Abdurrahman Aycan<sup>2</sup>, Burak Eren<sup>1</sup>, Necati Kaplan<sup>3</sup>, M. Murat Taskin<sup>4</sup>, Feyza Karagoz Guzey<sup>2</sup>



## ABSTRACT

**Objective:** To evaluate and compare the radiological changes on adjacent mobile segments and clinical findings in patients having undergone single-segment simple anterior cervical discectomy versus discectomy plus intervertebral fusion.

**Material and Methods:** Twenty-five patients were treated with discectomy plus fusion and 20 patients with simple discectomy. Clinical pictures of the patients were evaluated with ODOM criteria before and 1 year after operation, and their improvement rates were calculated.

The disc heights of superior and inferior adjacent segments, superior and inferior foramen heights, superior and inferior end plate heights of superior and inferior adjacent segments, new osteophyte development, segmental angulation and loss of cervical lordosis were evaluated on cervical radiographies before and 1 year after operation.

**Results:** Although there were new degenerative findings in adjacent mobile segments in all patients when preoperative and postoperative measurements were compared, these radiological findings did not translate into clinical findings. In the fusion group, radiological degeneration findings were seen more frequently statistically; however, clinical results were not different between the two groups. On the other hand, loss of lordosis was significantly more frequent in the simple discectomy group.

**Conclusion:** Although adding fusion to single-segment anterior cervical discectomy caused more frequent radiological degenerative changes in adjacent segments after 1 year compared to simple discectomy, clinical results were similar. It was thought that longer follow-up was necessary to observe clinical adjacent segment disease that was expected to become more frequent because of excessive mobility due to fusion.

**Keywords:** Discectomy, intervertebral disc displacement, spinal fusions - adverse effects

## ÖZET

Tek seviye anterior servikal diskektomi ile diskektomi ve füzyon sonrası radyolojik ve klinik komşu seviye dejenerasyonu oranlarının karşılaştırılması

**Amaç:** Tek seviye basit anterior servikal diskektomi uygulanan olgularda komşu seviyelerde gelişen radyolojik değişiklikleri ve klinik bulguları diskektomiyle birlikte füzyon uygulanan olgularda görülenlerle karşılaştırmak.

**Gereç ve Yöntemler:** Diskektomiyle birlikte füzyon uygulanan 25, basit diskektomi uygulanan 20 olgu vardı. Olguların klinik tabloları girişim öncesinde ve girişimden 1 yıl sonra ODOM kriterlerine göre değerlendirildi ve iyileşme oranları hesaplandı. Üst ve alt komşu seviyelerdeki disk yükseklikleri, üst ve alt foramen yükseklikleri, üst ve alt komşu seviyelerin üst ve alt son plaklarının yükseklikleri, yeni osteofit gelişimi, segmenter açılma ve servikal lordoz derecesi girişim öncesi ve girişimden 1 yıl sonraki grafilerde ölçüldü.

**Bulgular:** Girişim öncesi ve 1 yıl sonraki ölçümler karşılaştırıldığında bütün olgularda bütün komşu seviyelerde yeni dejeneratif değişiklikler ortaya çıkmasına rağmen radyolojik bulgular klinik bulgulara yansımamıştı. Füzyon grubunda radyolojik dejenerasyon bulguları anlamlı olarak daha sık olsa da klinik sonuçlar iki grupta aynıydı. Öte yandan, servikal lordoz kaybı basit diskektomi grubunda anlamlı olarak daha fazlaydı.

**Sonuçlar:** Tek seviye anterior servikal diskektomiye füzyon eklenmesi 1 yıl sonunda komşu seviyelerde daha sık radyolojik dejenerasyon bulgularına neden olsa da klinik bulgular aynıydı. Füzyonun neden olduğu aşırı harekete bağlı olarak gelişmesi beklenen klinik komşu seviye hastalığının görülebilmesi için daha uzun süreli izlem gerektiği düşünüldü.

**Anahtar kelimeler:** Diskektomi, intervertebral disk kayması, spinal füzyon - yan etkiler

<sup>1</sup>Bagcilar Training and Research Hospital, Department of Neurosurgery, Istanbul, Turkey

<sup>2</sup>Yuzuncuyil University, Faculty of Medicine, Department of Neurosurgery, Van, Turkey

<sup>3</sup>The Reyap Hospital, Department of Neurosurgery, Tekirdag, Turkey

<sup>4</sup>The Bodrum Hospital, Department of Neurosurgery, Mugla, Turkey

## Corresponding author:

Ozgur Yusuf Aktas

Bagcilar Training and Research Hospital, 6. Sokak Bagcilar, Istanbul, Turkey

Phone: +90-212-440-4000/1514

E-mail address: ozgurysuf@yahoo.com.tr

Date of submission: October 24, 2016

Date of acceptance: November 6, 2016

## Introduction

The anterior approach is the most frequently used operation technique in cervical disc disease today. To add fusion to discectomy has almost become the standard method for the last 50 years since it was defined for the treatment of degenerative spondylotic disease (1-3). To perform fusion plus discectomy has some advantages: It provides protection of disc height and thereby prevents the development of foraminal stenosis, it causes a loss of mobility of the operated segment, thus avoiding dynamic neural compression, and lastly, it provides stability and prevents the development of kyphotic deformity.

On the other hand, anterior cervical fusion is not a wholly innocent procedure, and especially its long-term effects may lead to new biomechanical and clinical consequences in the patient. Problems of segments adjacent to the fused segment due to excessive burden were frequently reported, especially in the last 2-3 decades. Accordingly, cervical discectomy without fusion was increasingly performed to prevent these problems.

In this study, we planned to evaluate retrospectively whether to add fusion to cervical discectomy causes acceleration of development of clinical and radiological degenerative changes in adjacent segments.

## Material and Methods

Patients having undergone single-segment anterior cervical discectomy in the 1. Neurosurgery Department of Dr. Mazhar Osman Bakirkoy Psychological and Neurological Diseases Training and Research Hospital between January 2003 to October 2005 were evaluated retrospectively, and those for whom adequate hospital clinical records were available and whose cervical radiographies were taken preoperatively and 1 year after operation were included in the study. Patients whose hospital records were inadequate or whose cervical radiographies were absent in the hospital charts were excluded. Patients having undergone single-segment cervical discectomy due to cervical trauma or tumor and those that had undergone discectomies in more than one segment were excluded. There were 45 patients matching the study criteria.

Surgical indications for cervical discectomy were: 1. resistant and severe pain after at least 3 weeks of conservative treatment, or 2. presence of radicular motor weakness, or 3. long tract signs, and 4. concordance of clinical picture and radiological findings (magnetic resonance imaging and/or computerized tomography).

All clinical, radiological, and electrophysiological findings, if present, in the preoperative and early postoperative periods and 1 year after operation were recorded.

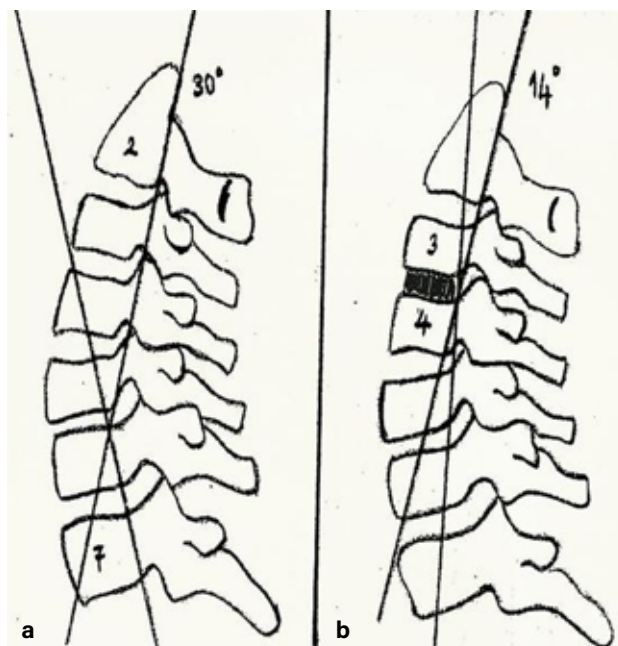
## Measurements

The disc height of superior and inferior adjacent segments, superior and inferior foramen heights, superior and inferior end plate heights of superior and inferior adjacent segments, segmental angulation and loss of cervical lordosis were measured, and new osteophyte development was evaluated on cervical radiographies taken before and 1 year after operation.

For cervical alignment evaluation, the angle between the lines passing the posterior borders of C2 and C7 vertebral bodies was measured (Figure 1 a). If the angle was  $<0$  degrees, cervical alignment was accepted as kyphotic; if it was 0 degrees, the alignment was accepted as neutral, and if it was  $>0$  degrees, the alignment was accepted as lordotic (4).

For evaluation of segmental angulation, the angle between lines passing the posterior borders of the superior and inferior vertebral bodies to the operated disc level was measured. If the angle was  $<0$  degrees, it was accepted as kyphotic, and if it was  $>1$  degree it was accepted as lordotic (4) (Figure 1 b).

Clinical results of the patients for pain and functional capacity on follow-up were evaluated with Odom Criteria (5), (Table 1).



**Figure 1: Measurement methods of cervical alignment (a) and segmental angulation (b).**

**Table 1: Odom criteria.**

I: Excellent result:	Neurologically full improvement
II: Good result	Partial improvement in pain and weaknesses; however, lifestyle is not affected
III: Moderate result:	The patient is independent, but unable to turn back to previous lifestyle due to neurological deficits
IV: Worse result:	There is no improvement of preoperative clinical picture or deterioration

**Table 2: Preoperative and 1-year follow-up radiological measurements.**

	ACDF			ACD		
	Preoperative	1 year	p	Preoperative	1 year	p
Sup. disc height	7.08±1.47	6.16±1.65	<b>0.005</b>	7.90±0.91	5.70±1.22	<b>0</b>
Inf. disc height	7.28±1.74	6.20±1.12	<b>0.001</b>	7.75±0.97	8.90±1.25	<b>0.002</b>
Sup. Foramen	10.12±1.99	9.36±2.2	<b>0</b>	11.30±1.72	10.95±1.82	0.167
Inf. Foramen	11.08±2.4	9.80±2.58	<b>0</b>	11.35±1.69	9.35±1.6	<b>0</b>
Sup. SEP	21.96±3.14	23.08±3.23	<b>0.001</b>	23.30±2.41	25.20±3	<b>0</b>
Inf. SEP	23.04±3.19	24.64±3.21	<b>0</b>	22.65±2.54	24.95±2.7	<b>0</b>
Sup IEP	21.92±3.5	23.12±3.81	<b>0</b>	23.15±3.17	25.65±3.18	<b>0.001</b>
Inf. IEP	22.40±2.96	24.16±2.97	<b>0</b>	22.6±2.52	24.55±2.19	<b>0</b>

SEP: Superior end plate; IEP: Inferior end plate.  
Significant p values have been marked with bold character.

## Surgical Procedures

All operations were performed under general anesthesia. In 20 patients, single-segment simple anterior cervical discectomy (ACD), and in 25, discectomy plus intervertebral fusion (ACDF) was performed. PEEK or titanium cages filled with demineralized bone matrix, allograft bone chips, or synthetic bone graft were used for fusion.

## Statistical evaluation

In the statistical evaluation, for numerical variables, Student's t test and for nominal ordinary variables Pearson  $\chi^2$  test was used. If p values were <0.05, results were accepted as statistically significant.

## Results

The mean age of the patients in the ACDF groups was 45.2 (range: 30-60 years of age) and in the ACD groups it was 39.9 (range: 29-59 years) ( $p<0.001$ ). Male/female ratio was 9/16 in the ACDF group and 10/10 in the ACD group ( $p>0.05$ ). Duration of symptoms before surgery was on average 10 months (between 1 and 36 months). It was 11 and 9 months in the ACDF and ACD groups, respectively ( $p>0.05$ ).

The measurements performed on preoperative and postoperative cervical radiographies are shown in Table 2. In the ACDF group, the disc heights of superior and inferior adjacent segments and superior and inferior foramen heights 1

year after operation were statistically lower than preoperative levels ( $p<0.05$  for superior adjacent segment height and  $p<0.001$  for other measurements), and superior and inferior end plate heights of superior and inferior adjacent segments were statistically higher ( $p<0.001$  for both). In the ACD group, the inferior adjacent segment 1 year after operation was statistically narrower than preoperative levels ( $p<0.001$ ), and superior and inferior end plate heights were statistically wider ( $p<0.001$  for all). The other measurements were not found to be statistically significant.

While superior disc height was not statistically different between the two groups before operation ( $p>0.05$ ), it was statistically wider in the ACD group than in the ACDF group 1 year after operation ( $p<0.001$ ). There was no statistically significant difference for other measurements.

Kyphosis was found in 6 patients (24%), a neutral position in 17 (68%), lordosis in 2 (8%), and abnormal segmental angulation in 5 patients (20%) in the ACDF group before operation. After 1 year, there was neutral cervical alignment in only 2 patients (8%). In the others, alignment was lordotic and there was not segmental angulation in any patient. In the ACD group, a neutral position was measured in 5 patients (20%), and there was no abnormal segmental angulation. However, after 1 year, there was a loss of lordosis in 10 patients (50%), kyphosis in 1 (5%), and abnormal segmental angulation in one patient (5%). In preoperative measurements, kyphosis was statistically

**Table 3: New osteophyte development, cervical alignment and segmental angulation after year.**

	<b>ACD (n/%)</b>	<b>ACDF (n/%)</b>	<b>p</b>
New osteophyte			0.066
presence	15/60	17/85	
absence	10/40	3/15	
Alignment			0.018
Neural	19/76	7/35	
Lordotic	6/24	12/60	
Kyphotic	0/0	1/5	
Segmental angulation			0.444
presence	25/100	19/95	
absence	0/0	1/5	

Significant p values have been marked with bold characters.

significantly more frequent in the ACDF group. Segmental angulation was also more frequent; however, the difference between the two groups was not significant. The difference in the presence of kyphosis and segmental angulation between the two groups were statistically significant after 1 year follow-up ( $p < 0.05$ ); however, it was interesting to note that both kyphosis and segmental angulation were more frequent in the ACD group than the ACDF group contrary to the preoperative condition (Table 2).

There was a statistically significant improvement in clinical findings according to ODOM criteria after 1 year follow-up compared to the values before operation in both groups ( $p < 0.05$ ). The rate of excellent and good results after 1 year follow-up was 85% in the ACD group and 92% in the ACDF group, and the difference was not statistically significant ( $p > 0.05$ ) (Table 2).

## Discussion

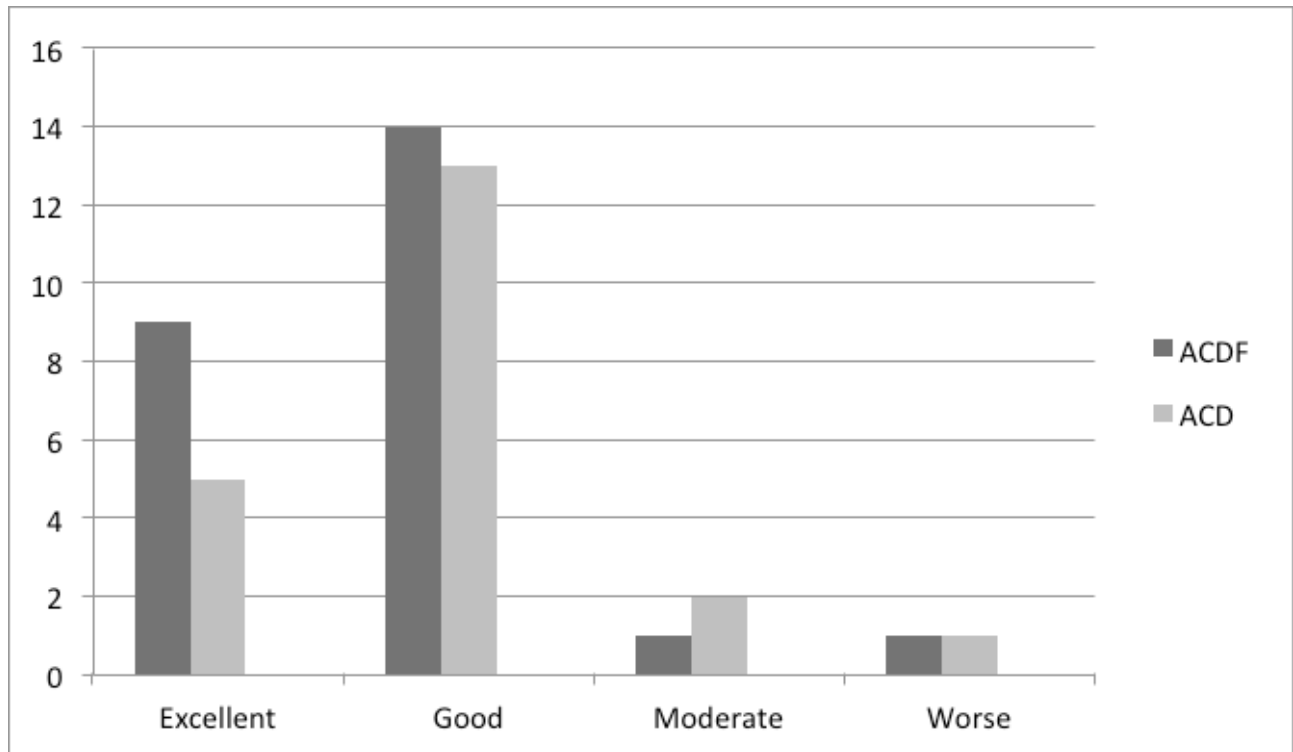
Spinal degeneration is a natural process due to aging. Spinal fusion is most frequently performed in the cervical spine, especially among segments C3-7, and it is well known that fusion in a mobile spinal segment causes acceleration of the degeneration process in the adjacent mobile segments. It is thought, according to biomechanical studies performed on this subject, that this acceleration is due to certain biomechanical changes causing an abnormal excessive burden in the adjacent segments (6,7).

The term "adjacent segment degeneration" is introduced to describe radiological degenerative changes in the adjacent segments above and below to the fused spinal segment. These changes include new osteophyte development, intervertebral disc degeneration, facet joint hypertrophy, and spinal canal

stenosis. However, clinical complaints and signs are not always associated with the radiological changes. If there are clinical signs and symptoms, the process is called adjacent segment disease. In this condition, new onset radiculopathy and/or myelopathy signs and symptoms are found in the patient (8,9).

There are many studies evaluating this condition found in the literature. Bohlman et al. (7) reported that adjacent segment disease was seen in 9% out of 122 patients undergoing ACDF after 6 years' follow-up. This rate was 14% in the series reported by Gore (15) after 5 years' follow-up. In the series reported by Henderson et al. (11) that included 846 patients undergoing ACD, 76 patients required new surgery due to adjacent segment disease, and the authors reported a prevalence of 9% and an incidence of 3%. Ishihara et al. (12) saw adjacent segment disease in 19 out of 112 patients (16.9%) undergoing ACDF and reported that 5-year disease free survival was 89%, 10-year survival was 84% and 17-year survival was 67%. Robertson et al. (13) reported in a series consisting 158 patients treated with ACDF that there were new degeneration signs such as new osteophyte development or growing of older ones, narrowing of the intervertebral discs, and calcification of the anterior longitudinal ligament in segments adjacent to the fused ones in 74 patients after 2 years' follow-up. Baba et al. (14) followed 100 patients undergoing ACDF for 8.5 years and reported 25% new onset degeneration in the upper segment of the fused segment. Gore (15) reported worsening of older degeneration signs in 25% of 146 patients after 5 years' follow-up. In another study, yearly frequency of development of adjacent segment disease was calculated as 1.5 to 4% after anterior cervical discectomies (15).

Some studies compare cervical discectomies with and



**Figure 2: Clinical results with ODOM criteria of the groups after 1-year follow-up.**

without fusion to evaluate whether own of fusion is the primary cause of adjacent segment disease. Lunsford et al. (16) found that adjacent segment disease developed in only 22 out of 253 patients undergoing ACD or ACDF, and interestingly, there was no difference between the two groups. In a comparative radiological study performed by Herkowitz et al. (17), 44 patients were followed for 4.5 years and adjacent segment degeneration developed in 41% of the patients in the ACDF group. However, the authors did not find a correlation between radiological and clinical findings of adjacent segment degeneration.

In our study, we saw that radiological adjacent segment disease findings were statistically more frequent in the single-segment ACDF group than in the ACD group even at 1-year follow-up, being a very short period for spinal degeneration. However, we did not find a relationship between radiological and clinical findings, as was the case in the study by Herkowitz et al. (17).

One of the important aims of fusion after cervical discectomy is to prevent narrowing of the disc space and loss of cervical alignment. Really, development of segmental

kyphosis was significantly more frequent in the ACD group after 1-year follow-up in our study. In addition, most of the preoperative segmental abnormalities improved after operation in the ACDF group. These findings showed that application of fusion after cervical discectomy helps improving preoperative alignment problems; however, ACD without fusion may cause new-onset alignment problems probably because of narrowing of the disc space. It was reported that abnormal movements due to these alignment issues may also cause adjacent segment problems (7,13,16,18-23): Either immobilization of the previously mobile segment with fusion or excessive mobilization of the segment undergoing ACD without fusion may cause acceleration of degeneration in the segments adjacent to the operated level.

In a study with 409 patients evaluating factors affecting development of adjacent segment disease, risk factors including the presence of neural tissue pressure and operations performed in C5-6 and C6-7 levels were determined. Surprisingly, the authors found that application of multiple-level fusions lessened the frequency of adjacent segment disease (18% to 12% for single-segment and multiple-segment fusions, respectively;

$p < 0.001$ ). Those study results suggested that the primary cause of adjacent segment disease may be natural progression of cervical spondylosis (24).

In conclusion, we found that adjacent segment degeneration started in early period after both cervical discectomies with and without fusions. Radiological findings were more frequent in the fusion group; however, there was no difference between the two groups for clinical disease. Nevertheless, it must be kept in mind that spinal degeneration is a very long process, and different results may be found in longer follow-up.

Contribution Categories	Name of Author
Development of study idea	O.Y.A., F.K.G., A.A.
Methodological design of the study	N.K., A.A., F.K.G.
Data acquisition and process	O.Y.A., A.A., F.K.G.
Data analysis and interpretation	O.Y.A., N.K., B.E.
Literature review	M.T., B.E., N.K.
Manuscript writing	M.T., B.E., N.K.
Manuscript review and revision	M.T., F.K.G., O.Y.A.

**Conflict of Interest:** Author declared no conflict of interest.

**Financial Disclosure:** Authors declared no financial support.

## References

- Bailey RW, Badgley CE. Stabilization of the cervical spine by anterior fusion. *J Bone Joint Surg Am* 1960;42-A:565-594.
- Cloward RB. Complications of anterior cervical disc operation and their treatment. *Surgery* 1971;69(2):75-182.
- Smith GW, Robinson RA. The treatment of certain cervical spine disorders by anterior removal of the intervertebral disc and interbody fusion. *J Bone Joint Surg Am* 1958;40A(3):607-624.
- Harrison DE, Harrison DD, Caillet R, Trovanovich SJ, Janik TJ, Holland B. Cobb method or Harrison posterior tangent method: Which to choose for lateral cervical radiographic analysis. *Spine (Phila Pa 1976)* 2000;25(16):2072-2078. [[CrossRef](#)]
- Odom GL, Finney W, Woodhall B. Cervical disc lesions. *J Am Med Assoc* 1958;166(1):223-228. [[CrossRef](#)]
- Goffin J, vanLoon J, Van Calenbergh F, Plets C. Long-term results after anterior cervical fusion and osteosynthetic stabilization for fractures and/or dislocations of the cervical spine. *J Spinal Disord* 1995;8(6):500-508. [[CrossRef](#)]
- Bohlman HH, Emery SE, Goodfellow DB, Jones PK. Robinson anterior cervical discectomy and arthrodesis for cervical radiculopathy. Long-term follow-up of one hundred and twenty-two patients. *J Bone Joint Surg Am* 1993;75(9):1298-1307.
- Song KJ, Choi BW, Jeon TS, Lee KB, Chang H. Adjacent segment degenerative disease: is it due to disease progression or a fusion-associated phenomenon? Comparison between segments adjacent to the fused and non-fused segments. *Eur Spine J* 2011;20(11):1940-1945. [[CrossRef](#)]
- Carrier CS, Bono CM, Lebl DR. Evidence-based analysis of adjacent segment degeneration and disease after ACDF: a systematic review. *Spine J* 2013;13(10):1370-1378. [[CrossRef](#)]
- Wang J, Mc Donough PW, Endow KK, Delamarter RB. Increased fusion rates with cervical plating for two level anterior cervical discectomy and fusion. *Spine (Phila Pa 1976)* 2000;25(1):41-45. [[CrossRef](#)]
- Henderson, Hennessy RG, Shuey HM Jr, Shackelford EG. Posterior lateral for laminotomy, as an exclusive operative technique for cervical radiculopathy: a review of 846 consecutively operated cases. *Neurosurgery* 1983;13(5):504-512. [[CrossRef](#)]
- Ishihara H, Kanamori M, Kawaguchi Y, Nakamura H, Kimura T. Adjacent segment disease after anterior cervical interbody fusion. *Spine J* 2004;4(6):624-628. [[CrossRef](#)]
- Robertson JT, Papadopoulos SM, Traynelis VJ. Assessment of adjacent-segment disease in patients treated with cervical fusion or arthroplasty. *J Neurosurg Spine* 2005;3(6):417-423. [[CrossRef](#)]
- Baba H, Furusawa N, Imura S, Kawahara N, Tsuchiya H, Tomita K. Late radiographic findings after anterior cervical fusion or spondylotic myeloradiculopathy. *Spine (Phila Pa 1976)* 1993;18(15):2167-2173. [[CrossRef](#)]
- Gore DR. The arthrodesis rate in multilevel anterior cervical fusions using autogenous fibula. *Spine (Phila Pa 1976)* 2001; 26(11):1259-1263. [[CrossRef](#)]
- Lunsford LD, Bissonette DJ, Jannetta PJ, Sheptak PE, Zorub DS. Anterior surgery for cervical disc disease, part 1: Treatment of lateral cervical disc herniation in 253 cases. *J Neurosurg* 1980;53(1):1-11. [[CrossRef](#)]
- Herkowitz HN, Kurz LT, Overholt DP. Surgical management of cervical soft disc herniation: a comparison between the anterior and posterior approach. *Spine (Phila Pa 1976)* 1990;15(10):1026-1030. [[CrossRef](#)]
- Capen DA, Garland DE, Waters RL. Surgical stabilization of cervical spine. A comparative analysis of anterior and posterior spine fusions. *Clin Orthop Relat Res* 1985;(196):229-237. [[CrossRef](#)]
- Herkowitz HN. The surgical management of cervical spondylotic radiculopathy and myelopathy. *Clin Orthop Relat Res* 1989;(239):94-108.
- Mayr MT, Subach BR, Comey CH, Rodts GE, Haid RW Jr. Cervical spinal stenosis: Outcome after anterior corpectomy, allograft reconstruction, and instrumentation. *J Neurosurg* 2002;96(Suppl1):10-16. [[CrossRef](#)]
- Roberto Assietti MD, Berrelta F, Anenta C. Two level anterior cervical discectomy and cage-assisted fusion with plates. *Neurosurg Focus* 2002;12(1):E3.
- Savolainen S, Rinne J, Hernesniemi J. A prospective randomized study of anterior single-level cervical disc operations with long-term follow-up: surgical fusion is unnecessary. *Neurosurgery* 1998;43(1):51-55. [[CrossRef](#)]
- Kettler A, Wilke HJ, Claes L. Effects of neck movements on stability and subsidence in cervical interbody fusion: an in vitro study. *J Neurosurg* 2001;94(Suppl1):S97-S107. [[CrossRef](#)]
- Hillibrand AS, Robbins M. Adjacent segment degeneration and adjacent segment disease: the consequences of spinal fusion? *Spine J* 2004;4(Suppl6):S190-S194. [[CrossRef](#)]