

Glomus Tumors of 20 Cases' Experience

Glomus Tümörlerinde 20 Olguluk Deneyim

 Muhammed Uslu¹,  Nilsen Yıldırım Erdoğan²,  Ozan Beytemür¹

¹University of Health Sciences Turkey, İstanbul Bağcılar Training and Research Hospital, Department of Orthopedics and Traumatology, İstanbul, Turkey

²University of Health Sciences Turkey, Başakşehir Çam and Sakura City Hospital, Department of Pathology, İstanbul, Turkey

Abstract

Objective: This study aimed to analyze the clinical characteristics, surgical outcomes, and long-term follow-up of glomus tumors in a single-center experience.

Method: A retrospective analysis was conducted on 20 patients who underwent surgery for histologically confirmed glomus tumors between 2013 and 2023. Patient demographics, tumor characteristics, clinical presentation, radiological findings, surgical outcomes, and follow-up data were collected and analyzed.

Results: The cohort consisted of 75% females, with a mean age of 45.5±17.3 years. Most tumors (85%) were located in the hand, with 65% in the subungual region. The most common symptoms were tenderness (100%), visible tumor (85%), cold sensitivity (80%), and pain (70%). Radiological findings were positive in 70% of cases. The median tumor size was 0.6 cm, with significantly larger tumors in males compared to females (p=0.0245). The median preoperative duration was two years, and the median follow-up was 3.5 years. A 5% recurrence rate was observed post-surgery.

Conclusion: This study provides valuable insights into the clinical presentation and surgical management of glomus tumors. The findings highlight the effectiveness of surgical excision, with a low recurrence rate. The correlation between positive radiological findings and longer preoperative duration suggests potential diagnostic delays, emphasizing the need for increased awareness and prompt intervention in suspected cases.

Keywords: Clinical characteristics, glomus tumor, hand tumors, long-term follow-up, radiological findings, subungual tumors, surgical excision

Öz

Amaç: Bu çalışmada tek merkezli bir deneyimde glomus tümörlerinin klinik özellikleri, cerrahi sonuçları ve uzun dönem takiplerinin analiz edilmesi amaçlandı.

Yöntem: 2013-2023 yılları arasında histolojik olarak doğrulanmış glomus tümörü nedeniyle ameliyat edilen 20 hasta üzerinde retrospektif bir analiz yapıldı. Hasta demografisi, tümör özellikleri, klinik prezentasyon, radyolojik bulgular, cerrahi sonuçlar ve takip verileri toplandı ve analiz edildi.

Bulgular: Kohort, ortalama yaşı 45,5±17,3 yıl olan %75 kadın hastadan oluşuyordu. Tümörlerin çoğu (%85) elde ve %65'i subungual bölgede yerleşmişti. En yaygın semptomlar hassasiyet (%100), görünür tümör (%85), soğuk hassasiyeti (%80) ve ağrı (%70) idi. Radyolojik bulgular olguların %70'inde pozitif. Ortanca tümör boyutu 0,6 cm idi ve erkeklerde kadınlara kıyasla anlamlı olarak daha büyük tümörler vardı (p=0,0245). Ameliyat öncesi medyan süre iki yıl ve medyan takip süresi 3,5 yıldır. Cerrahi sonrası %5 nüks oranı gözlemlendi.

Sonuç: Bu çalışma glomus tümörlerinin klinik görünümü ve cerrahi yönetimi hakkında değerli bilgiler sağlamaktadır. Bulgular, düşük nüks oranı ile cerrahi eksizyonun etkinliğini vurgulamaktadır. Pozitif radyolojik bulgular ve daha uzun preoperative süre arasındaki korelasyon, potansiyel tanısal gecikmelere işaret etmekte ve şüpheli olgularda farkındalığın artırılması ve hızlı müdahale ihtiyacını vurgulamaktadır.

Anahtar kelimeler: Cerrahi eksizyon, el tümörleri, glomus tümörü, klinik özellikler, radyolojik bulgular, subungual tümörler, uzun dönem takip



Address for Correspondence: Muhammed Uslu, University of Health Sciences Turkey, İstanbul Bağcılar Training and Research Hospital, Department of Orthopedics and Traumatology, İstanbul, Turkey

E-mail: dr.muhammeduslu@gmail.com **ORCID:** orcid.org/0000-0002-1810-2713

Received: 30.09.2024 **Accepted:** 20.05.2025 **Epub:** 26.05.2025 **Publication Date:** 24.06.2025

Cite this article as: Uslu M, Yıldırım Erdoğan N, Beytemür O. Glomus tumors of 20 cases' experience. Bagcilar Med Bull. 2025;10(2):169-175



©Copyright 2025 by the Health Sciences University Turkey, İstanbul Bağcılar Training and Research Hospital. Bagcilar Medical Bulletin published by Galenos Publishing House. Licensed under a Creative Commons Attribution-NonCommercial-NoDerivatives 4.0 (CC BY-NC-ND) International License.

Introduction

Glomus tumors are rare neoplasms arising from the glomus body in the dermis, which provides thermoregulation (1,2). Glomus bodies are specialized neuromyoarterial structures with a delicate network of arteriovenous anastomoses regulating blood flow through the skin to control blood pressure and temperature. First described by Wood (3) in 1812, glomus tumours were identified as subcutaneous nodules on the fingers of the upper extremities (1,2). Subsequently, case reports occurred in various parts of the body, including internal organs such as the stomach and kidney (1,4). Clinically, glomus tumors are difficult to diagnose. Non-specific symptoms and usual physical examination findings often lead to misdiagnosis and incorrect treatment. Some patients may experience prolonged pain due to delays in diagnosis. The difficulty in diagnosis is often due to the small size of the tumor; the lesion may not be visible on physical examination and radiological imaging (5). In 1972, Roberte and Arnoldt (6) described the classic symptoms of glomus tumors as pain, tenderness and cold sensitivity. These three symptoms have been shown to allow for diagnosis in 90% of patients (7). Physical examination findings include Love's test (needle tip tenderness) and Hildreth's sign (decrease in pain/sensitivity after inflation of a tourniquet above systolic blood pressure proximal to the tumour) (8-10).

In addition to the clinical findings, radiological imaging is used to confirm the diagnosis. Scalloping of the bone can be seen on plain radiographs, albeit at a low rate (11). High-resolution magnetic resonance imaging (MRIs) are useful for detecting small tumors during diagnosis (12). However, there are also tumors that are not detected on MRI but are seen intraoperatively and excised. Studies have shown that high-resolution ultrasound is also useful for diagnosis (13).

Glomus tumors are histologically well-circumscribed nodules consisting of uniform round cells that are typically located perivascularly. These tumors are composed of glomus cells, blood vessels, and smooth muscle cells. Based on the distribution of these three components, they are divided into three histological subtypes: Glomus solid tumors, glomangiomas, and glomangiomyomas. There are very few smooth muscle and blood vessel components in glomus tumors. Blood vessels are prominent in glomangiomas. Smooth muscles and blood vessels are equally dominant in glomangiomyomas (14).

With our comprehensive analysis, we hope to provide valuable insights into the management of glomus tumors.

We are pleased to present a series of 20 glomus tumor cases, one of the largest case series from a single institution. Our study aimed to elucidate the clinical features of this rare neoplasm.

Materials and Methods

Patient Selection

A retrospective analysis was conducted on the medical records of 20 individuals who underwent surgical treatment for glomus tumors at our orthopedic and trauma center from 2013 to 2023. The investigation took place in a single tertiary healthcare facility, with the research protocol receiving approval from the Institutional Ethics Committee of University of Health Sciences Turkey, İstanbul Bağcılar Training and Research Hospital (protocol number: 2024/04/03/040, date: 29/04/2024). To be included in the study, participants had to be at least 18 years old, have a histologically confirmed glomus tumor diagnosis, and have a minimum one-year follow-up period. The study excluded patients with insufficient follow-up documentation or uncertain pathological diagnoses. Initially, 23 potential candidates were identified from hospital records. However, three were subsequently excluded due to lack of clinical follow-up. The final study group comprised 20 patients with confirmed glomus tumors, all of whom underwent surgery and received clinical follow-up care from a single orthopedic surgeon at the aforementioned tertiary care hospital.

Data Collection

A comprehensive database system was developed to compile various details using hospital records. This form included patient demographics, preoperative imaging results, thorough surgical notes, and physical examination findings of the affected area. The collected information encompassed the patient's age, gender, tumor location, duration of symptoms before surgery, tumor recurrence as a postoperative issue, length of follow-up after surgery, patient's dominant hand, any history of injury, and imaging study results.

Operation

A single surgeon performed all operations. Surgical procedures involved making incisions in the appropriate anatomical area of the lesion, adhering to oncological surgery principles. The surgeon prioritized removing masses in one piece while carefully preserving crucial nearby structures, such as the nail bed, and ensuring no satellite lesions remained (Figure 1).

The excised masses were then preserved for pathological examination. For subungual region masses, the surgeon first removed the nail; then made a longitudinal incision in the nail bed and nail fold. Following mass excision, the area was repaired using two 4-0 vicryl sutures, and the previously removed nail was placed over the wound to serve as a biological dressing (Figure 2).

Histopathological Analysis

A single pathologist conducted the histopathological evaluation of the specimens. The largest dimension and visual characteristics of the tumors were documented macroscopically. Standard tissue processing methods, along with hematoxylin and eosin staining and immunohistochemical analyses, were employed on the samples. Microscopic examination confirmed the diagnosis of glomus tumors. All findings were documented in the patient records.

Follow-up

Post-operative care involved unrestricted movement and the initiation of active motion once pain subsided. Patients underwent examination and wound site evaluation after two weeks, with subsequent follow-up appointments scheduled. During these visits, patients reported that the area where the nail was surgically removed had healed naturally during later dressings, and a new nail had emerged. The follow-up sessions documented various complications, including recurrence, limitations in joint mobility, nail abnormalities, nail discomfort, sensitivity, and issues at the wound site. The duration of follow-up ranged from 13 to 110 months.

Statistical Analysis

The GraphPad Instat ver. 3.06 (GraphPad Inc, CA, USA) software was used to conduct statistical analyses. To determine the distribution of variables, the Kolmogorov-Smirnov test was used. For comparing two normally distributed continuous variables, an unpaired t-test was applied, while One-Way Analysis of Variance (ANOVA) was used for comparing more than two such variables. In cases of non-normally distributed continuous variables, the Mann-Whitney U test was employed for comparing two groups, and the Kruskal-Wallis test was used for more than two variables. Comparisons of categorical variables were made using the chi-squared test for Independence. A p-value of less than 0.05 was considered statistically significant.

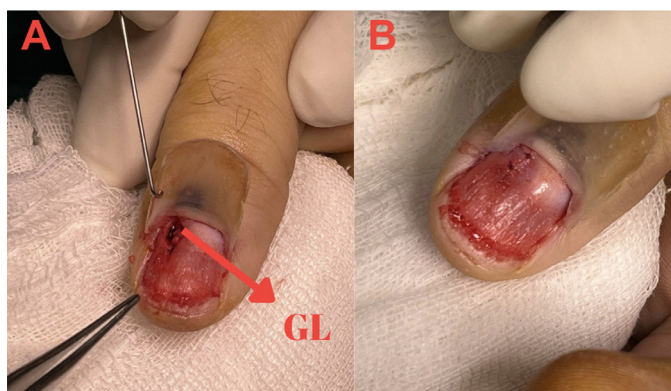


Figure 1. A: Intraoperative image of a glomus tumour (GL) in the nail bed of the thumb of the hand, B: Image of nail bed repair after GL excision

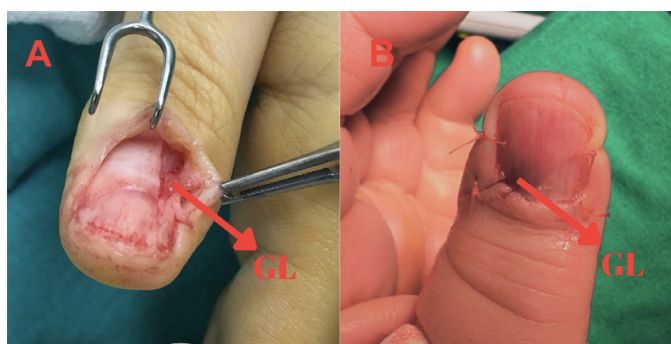


Figure 2. A: Intraoperative image of a glomus tumour (GL) in the nail bed of the thumb, B: Replacement of the nail as a biological dressing after excision of GL. Note the discolouration of the nail bed

Results

Twenty patients were evaluated. The mean age was 45.5 ± 17.3 years, with 75% of the cohort comprising female participants and 25% male participants. Most of the tumors were located in the hand (85%), with 65% of these tumors specifically in the subungual region. On histological examination, the tumors were identified as glomus tumors in 90% of the cases, with the remaining 10% classified as glomangiomas (Table 1). The most frequently reported symptoms were tenderness (100%), the presence of a visible tumor (85%), cold sensitivity (80%), and pain (70%). Nail changes were observed in 20% of the patients (Figure 3). A history of trauma was documented in 10% of the cases. Radiological findings were positive in 70% of patients, with a median tumour size of 0.6 cm (range: 0.3-2.0 cm). The median preoperative duration was two years (range: 0.25-10 years), and the median follow-up duration was three and a half years (range: one to nine years). Recurrence was observed in one patient, representing 5% of the total number of cases.

Table 1. Demographics and clinicopathological features of all patients

		Total (n=20)
Age, mean \pm SD	Year	45.5 \pm 17.3
Gender, n (%)	Male	5 (25)
	Female	15 (75)
Tumor location, n (%)	Hand	17 (85)
	Fingernail	13 (65)
	Subcutaneous region	4 (20)
	Others*	3 (15)
Side, n (%)	Left	13 (65)
	Right	7 (35)
Type of tumor, n (%)	Glomus	18 (90)
	Glomangioma	2 (10)
Symptoms, n (%)	Pain	14 (70)
	Tenderness	20 (100)
	Cold sensitivity	16 (80)
	Visible tumor	17 (85)
	Nail changes	4 (20)
History of trauma, n (%)		2 (10)
Radiological findings, n (%)		14 (70)
Tumor size, median [range]	Largest dimension (cm)	0.6 [0.3-2.0]
Preoperative duration, median [range]	Year	2 [0.25-10]
Duration of follow-up, median [range]	Year	3.5 [1-9]
Recurrence, n (%)		1 (5)

SD: Standard deviation, *: 1 case in knee, 1 case in shoulder and 1 case in cruris

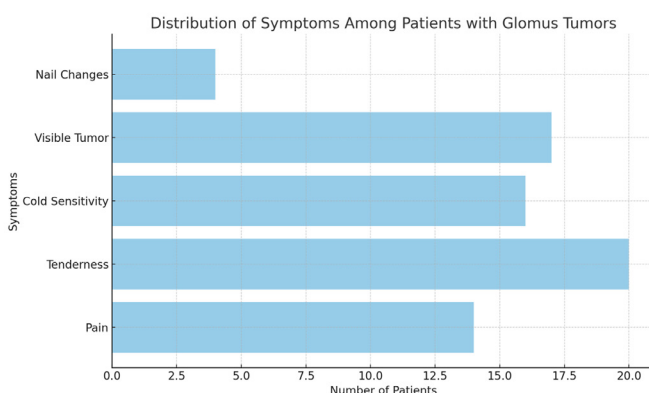


Figure 3. Distribution of symptoms among patients with glomus tumors. The bar chart illustrates the frequency of various symptoms observed in patients with glomus tumors. Tenderness was the most common symptom, reported by 100% of the patients, followed by visible tumors (85%), cold sensitivity (80%), and pain (70%). Nail changes were observed in 20% of the patients

A comparison of the sexes revealed no significant differences in mean age ($p=0.898$) but a significant difference in tumor location ($p=0.0114$). However, a significant difference was observed in tumor size between the two sexes. Median

tumour size was 6 mm. The median size of the tumors was 1.0 cm (range: 0.9-2.0 cm); in males, it was 0.5 cm (range: 0.3-0.7 cm), in females ($p=0.0245$). Recurrence was observed in 6.6% of the female patients, whereas no recurrence was noted in the male patients (Table 2).

Radiological Findings

A comparison of patients based on the presence of radiological findings revealed no significant differences in terms of age ($p=0.444$), sex ($p=0.573$), or tumor size ($p>0.999$). However, the preoperative duration was significantly longer in patients with positive radiological findings [median: 3.0 years (range: 0.5-10.0 years)] than in those without [median: 1.0 year (range: 0.25-2.0 years)] ($p=0.0261$). Recurrence was observed in 7.1% of the patients with radiological findings, whereas no recurrence was noted in those without such findings (Table 3).

Discussion

The most significant aspect of our study is that it is one of the largest single-center series with a long follow-up period (15,16). One of the most significant findings was that 70% of patients exhibited radiological findings, which increased in prevalence in correlation with the duration of preoperative waiting time.

Demographic data indicated a higher prevalence of glomus tumors in women (75%), which is consistent with existing literature (17,18). The mean age of 45.5 \pm 17.3 years suggests that glomus tumors predominantly affect middle-aged adults.

Glomus tumors can present at a wide range of anatomical sites beyond the classic subungual location. The literature documents cases of glomus tumors in various extradigital and visceral sites, which can pose diagnostic challenges due to their rarity and potential for atypical presentation. Recognition of these diverse locations is crucial for accurate diagnosis and management of glomus tumors (19,20). The majority of tumors were located in the hand (85%), with a particular predilection for the subungual region (65%). This localization pattern aligns with previous studies reporting that glomus tumors typically occur in the distal extremities.

Regarding symptomatology, tenderness (100%), visible tumor (85%), cold sensitivity (80%), and pain (70%) were the most frequently reported complaints. This symptom profile is consistent with the classic triad described by Roberte and Arnoldt (6), underscoring the importance of high clinical suspicion in the diagnosis of glomus tumours.

Imaging techniques, such as ultrasonography and MRI, play a significant role, with MRI being particularly valuable for identifying small tumors and assessing their extent. The

literature suggests that while MRI is a powerful diagnostic tool, its performance can be enhanced with additional techniques such as MR angiography to overcome its

Table 2. Comparison of demographics and clinicopathological features of patients according to the gender

		Male (n=5)	Female (n=15)	p-value
Age, mean \pm SD	Year	46.6 \pm 23.8	45.1 \pm 15.7	0.898
Tumor location, n (%)	Hand	2 (40)	15 (100)	0.0114
	Fingernail	2 (40)	11 (73.3)	0.417
	Subcutaneous region	0 (0)	4 (26.7)	0.519
	Others	3 (60)*	0 (0)	0.0114
Side, n (%)	Left	4 (80)	9 (60)	0.787
	Right	1 (20)	6 (40)	
Type of tumor, n (%)	Glomus	4 (80)	14 (93.3)	0.389
	Glomangioma	1 (20)	1 (6.7)	
Symptoms, n (%)	Pain	3 (60)	11 (73.3)	0.573
	Tenderness	5 (100)	15 (100)	-
	Cold sensitivity	3 (60)	13 (86.7)	0.519
	Visible tumor	2 (40)	15 (100)	0.0114
	Nail changes	1 (20)	3 (20)	1.00
History of trauma, n (%)		1 (20)	1 (6.7)	0.389
Radiological findings, n (%)		3 (60)	11 (73.3)	0.573
Tumor size, median [range]	Largest dimension (cm)	1.0 [0.9-2.0]	0.5 [0.3-0.7]	0.0245
Preoperative duration, median [range]	Year	1.0 [0.25-8.0]	2.0 [0.5-10.0]	0.570
Duration of follow-up, median [range]	Year	3.0 [1.0-7.0]	4.0 [1.0-9.0]	0.590
Recurrence, n (%)		0 (0)	1 (6.6)	0.554

Mann-Whitney U test or Unpaired t-test with Welch correction and chi-square, *: 1 case in knee, 1 case in shoulder and 1 case in cruris, SD: Standard deviation

Table 3. Comparison of demographics and clinicopathological features of patients according to the presence of radiological findings

		Without finding (n=6)	With finding (n=14)	p-value
Age, mean \pm SD	Year	39.8 \pm 22.1	47.9 \pm 15.2	0.444
Gender, n (%)	Male	2 (33.3)	3 (21.4)	0.573
	Female	4 (66.7)	11 (78.6)	
Tumor location, n (%)	Hand	5 (83.3)	12 (85.7)	0.891
	Fingernail	3 (50)	10 (71.4)	0.682
	Subcutaneous region	2 (33.3)	2 (14.3)	0.714
	Others*	1 (16.7)	2 (14.3)	0.891
Side, n (%)	Left	4 (66.7)	9 (64.3)	0.919
	Right	2 (33.3)	5 (35.7)	
Type of tumor, n (%)	Glomus	5 (83.3)	13 (92.9)	0.515
	Glomangioma	1 (16.7)	1 (7.1)	
Symptoms, n (%)	Pain	5 (83.3)	9 (64.3)	0.750
	Tenderness	6 (100)	14 (100)	-
	Cold sensitivity	5 (83.3)	11 (78.6)	0.807
	Visible tumor	5 (83.3)	12 (85.7)	0.891
	Nail changes	1 (16.7)	3 (21.4)	0.807
History of trauma, n (%)		0 (0)	2 (14.3)	0.871
Tumor size, median [range]	Largest dimension (cm)	0.6 [0.3-2.0]	0.6 [0.3-1.3]	>0.999
Preoperative duration, median [range]	Year	1.0 [0.25-2.0]	3.0 [0.5-10.0]	0.0261
Duration of follow-up, median [range]	Year	4.0 [2.0-7.0]	3.0 [1.0-9.0]	0.323
Recurrence, n (%)		0 (0)	1 (7.1)	0.502

Mann-Whitney U test or Unpaired t-test with Welch correction and chi-square, *: 1 case in knee, 1 case in shoulder and 1 case in cruris, SD: Standard deviation

limitations (21,22). Radiological findings were positive in 70% of patients, suggesting that imaging modalities can be beneficial in diagnosis, but may not be sufficient for a definitive diagnosis. Notably, patients with radiological findings had a longer preoperative symptom duration (median, 3 years vs. 1 year; $p=0.0261$), indicating potential diagnostic delays.

The significant difference in tumor size between genders (median 1.0 cm in males, 0.5 cm in females, $p=0.0245$) is noteworthy and may warrant further investigation. A comparison with similar studies in the literature reveals that the tumour size is larger than that reported (median 6 mm) (15,23). It was observed that the tumour size was larger in cases where a long preoperative waiting time had elapsed. It was therefore assumed that there was a direct correlation between tumour size and the length of time spent in preoperative waiting.

Current literature on recurrence rates following surgical intervention for glomus tumors is limited due to the rarity of these neoplasms. However, available studies generally indicate that surgical excision is an effective treatment modality, associated with low recurrence rates. Notably, in cases of subungual glomus tumors, surgical excision has been reported to alleviate symptoms with infrequent recurrence during follow-up period (24,25). The recurrence rate was 5%, which is consistent with the rates reported in the literature and demonstrates the efficacy of surgical excision as a treatment modality.

Study Limitations

It should be noted that our study is subject to certain limitations, including the relatively small number of patients included and the retrospective nature of the study. Furthermore, a comparison of preoperative and postoperative pain and functional scores was not possible.

Conclusion

This study provides valuable insights into the clinical characteristics and surgical outcomes of glomus tumors, drawing from a substantial single-center series with extended follow-up. Key findings include a predominance in female patients and in the hand, particularly in the subungual region, and the observation of the classic symptom triad in the majority of patients. Positive radiological findings were present in 70% of cases and correlated with a longer preoperative duration, while larger tumors were observed in male patients. The investigation reported a low recurrence rate of 5% following surgical

excision, underscoring the effectiveness of this treatment approach.

Ethics

Ethics Committee Approval: The investigation took place in a single tertiary healthcare facility, with the research protocol receiving approval from the Institutional Ethics Committee of University of Health Sciences Turkey, İstanbul Bağcılar Training and Research Hospital (protocol number: 2024/04/03/040, date: 29/04/2024).

Informed Consent: Participants were informed in detail, and verbal and written consent was obtained.

Footnotes

Authorship Contributions

Surgical and Medical Practices: M.U., Concept: O.B., N.Y.E., Design: O.B., Data Collection or Processing: N.Y.E., Analysis or Interpretation: N.Y.E., O.B., Literature Search: M.U., Writing: M.U.

Conflict of Interest: No conflict of interest was declared by the authors.

Financial Disclosure: The authors declared that this study received no financial support.

References

1. Trehan SK, Soukup DS, Mintz DN, Perino G, Ellis SJ. Glomus tumors in the foot. *Foot Ankle Spec.* 2015;8(6):460-465.
2. Romanos E, Al Delfi F, Hubballah M, Farah C. Glomus tumour of the fourth toe: case discussion and review of literature. *BMJ Case Reports.* 2019;12(11):e231100.
3. Wood W. On painful subcutaneous tubercle. *Edinb Med Surg J.* 1812;8:283-291.
4. Novis E, Raman A, Maclean F, Lazzaro E. Glomus tumour of the kidney: a case report and review of the literature. *ANZ J Surg.* 2016;88(6):653-654.
5. Abidin MA, Kitta MI, Nong I, Rahmansyah N, Johan MP. Diagnosis and surgical approach in treating glomus tumor distal phalanx left middle finger: a case report. *Int J Surg Case Rep.* 2023;108:108426.
6. Roberte C, Arnoldt B. Glomus tumors of the hand. *J Bone Joint Surg.* 1972;54(4):691-703.
7. Santoshi JA, Kori VK, Khurana U. Glomus tumor of the fingertips: a frequently missed diagnosis. *J Family Med Prim Care.* 2019;8(3):904-908.
8. Sethu C, Sethu AU. Glomus tumour. *Ann R Coll Surg Engl.* 2016;98(1):e1-e2.
9. Polo C, Borda D, Poggio D, Asunción J, Peidro L. Glomus tumor of the hallux review of the literature and report of two cases. *Foot Ankle Surg.* 2012;18(2):89-93.
10. Lee WQ, Li Y, Yeo NEM. Glomus tumour: an institutional experience of 31 cases. *J Orthop Surg Res.* 2023;18(1):741.

11. Van Geertruyden J, Lorea P, Goldschmidt D, de Fontaine S, Schuind F, Kinnen L, et al. Glomus tumours of the hand. A retrospective study of 51 cases. *J Hand Surg Br.* 1996;21(2):257-260.
12. Fujioka H, Kokubu T, Akisue T, Nagura I, Toyokawa N, Inui A, et al. Treatment of subungual glomus tumor. *Kobe J Med Sci.* 2009;55(1):E1-E4.
13. Chen SH, Chen YL, Cheng MH, Yeow KM, Chen HC, Wei FC. The use of ultrasonography in preoperative localization of digital glomus tumors. *Plast Reconstr Surg.* 2003;112(1):115-119; discussion 120.
14. Kim SH, Suh HS, Choi JH, Sung KJ, Moon KC, Koh JK. Glomus tumor: a clinical and histopathologic analysis of 17 cases. *Ann Dermatol.* 2000;12(2):95-101.
15. Saaq M. Presentation and management outcome of glomus tumors of the hand. *Arch Bone Jt Surg.* 2021;9(3):312-318.
16. Uslu M, Erdoğan NY, Daşcı ME, Beytemür O. Twelve-year experience for tenosynovial giant cell tumors of tendon sheath: a review of 95 cases from a single institution. *Bagcilar Med Bull.* 2024;9(2):114-120.
17. Çevik HB, Çiçek ÇA, Kayahan S, Gümüstas SA, Filinte GT. Glomus tumors of the upper extremity. *Handchir Mikrochir Plast Chir.* 2021;53(1):72-75.
18. Abou Jaoude JF, Roula Farah A, Sargi Z, Khairallah S, Fakih C. Glomus tumors: report on eleven cases and a review of the literature. *Chir Main.* 2000;19(4):243-252.
19. Nandi D, Zadte KM, Dhal I. Pair of glomus tumors in thigh –both periosteal and intramuscular: rare tumor in atypical location. *Indian J Musculoskelet Radiol.* 2021;3(2):121-124.
20. Beytemür O, Adanır O, Tetikkurt ÜS, Güleç MA. Glomus tumor located in deltoid muscle. *Acta Orthop Traumatol Turc.* 2016;50(2):242-244.
21. Drapé JL. Advances in MRI of glomus tumors of the fingertips. *Advances in Nail Disease and Management.* 2021;33-45
22. Glazebrook KN, Laundre BJ, Schiefer TK, Inwards CY. Imaging features of glomus tumors. *Skeletal Radiol.* 2011;40(7):855-862.
23. Mravic M, LaChaud G, Nguyen A, Scott MA, Dry SM, James AW. Clinical and histopathological diagnosis of glomus tumor: an institutional experience of 138 cases. *Int J Surg Pathol.* 2015;23(3):181-188.
24. Song M, Kim MB, Ko HC, Kwon KS. Surgical treatment of subungual glomus tumor. *Dermatol Surg.* 2009;35(5):786-791.
25. Jiang H, Wu C. Clinical analysis of surgical treatment for subungual glomus tumor. *Chinese Journal of Hand Surgery.* 2018;34(4):278-280.