

# Superficial Cervical Plexus Block for Postoperative Pain Management in Patients Undergoing Supraglottic Laryngectomy and Bilateral Neck Dissection: A Case Series

## Supraglottik Larenjektomi ve Bilateral Boyun Diseksiyonu Yapılan Hastalarda Postoperatif Ağrı Yönetiminde Yüzeyel Servikal Pleksus Bloğu Uygulaması: Olgu Serisi

Onur Sarban<sup>1</sup>, Özal Adıyeke<sup>1</sup>, Ergün Mendeş<sup>1</sup>, Engin İhsan Turan<sup>2</sup>, Funda Gümüş Özcan<sup>1</sup>

<sup>1</sup>University of Health Sciences Turkey, Başakşehir Çam ve Sakura City Hospital, Clinic of Anesthesiology and Reanimation, İstanbul, Turkey

<sup>2</sup>University of Health Sciences Turkey, İstanbul Kanuni Sultan Süleyman Training and Research Hospital, Clinic of Anesthesiology and Reanimation, İstanbul, Turkey

### Abstract

Superficial cervical plexus block (SCPB) has been widely utilized in anesthesia and analgesia management for head and neck surgeries. This case series aims to share our experience with SCPB for postoperative analgesia in patients undergoing supraglottic laryngectomy, bilateral neck dissection, and tracheostomy due to laryngeal carcinoma. SCPB was administered to 10 patients aged over 18 years with an ASA score of 2 or 3, who underwent supraglottic laryngectomy, bilateral neck dissection, and tracheostomy between January 15, 2023, and March 15, 2023. The blocks were performed using ultrasonography guidance with 0.1 mL/kg of 0.25% bupivacaine. Routine anesthesia induction was followed by maintenance with 2% sevoflurane and intravenous remifentanyl infusion. Postoperative pain was assessed using the numeric rating scale (NRS) at 1, 6, 12, and 24 hours. The average NRS scores were 1.6 at 1 hour, 2.3 at 6 hours, 2.4 at 12 hours, and 2.4 at 24 hours postoperatively. SCPB was effective in reducing postoperative pain, with minimal additional analgesia required. No complications related to SCPB were observed.

SCPB provides effective postoperative pain management for patients undergoing supraglottic laryngectomy and bilateral neck dissection, with a favorable safety profile. However, further studies with larger sample sizes and comparison groups are needed to validate these findings.

**Keywords:** Cervical plexus block, head and neck surgery, regional anesthesia, tracheostomy

### Öz

Süperfişyal servikal pleksus bloğu (SCPB), baş ve boyun cerrahilerinde anestezi ve analjezi yönetiminde yaygın olarak kullanılmaktadır. Bu olgu serisi, larinks karsinomu nedeniyle supraglottik larenjektomi, bilateral boyun diseksiyonu ve trakeostomi uygulanan hastalarda SCPB ile postoperatif analjezi yönetimindeki deneyimlerimizi paylaşmayı amaçlamaktadır. 15 Ocak 2023 ile 15 Mart 2023 tarihleri arasında supraglottik larenjektomi, bilateral boyun diseksiyonu ve trakeostomi yapılan, ASA skoru 2 veya 3 olan 18 yaş üzeri 10 hastaya SCPB uygulandı. Bloklar, ultrasonografi rehberliğinde, %0,25 bupivakainin 0,1 mL/kg'lik dozu ile gerçekleştirildi. Rutin anestezi indüksiyonunu takiben, %2 sevofluran ve intravenöz remifentanil infüzyonu ile idame sağlandı. Postoperatif ağrı, 1, 6, 12 ve 24 saatlerde sayısal derecelendirme skalası (NRS) kullanılarak değerlendirildi. Ortalama NRS skorları postoperatif 1. saatte 1,6, 6. saatte 2,3, 12. saatte 2,4 ve 24. saatte 2,4 olarak kaydedildi. SCPB, postoperatif ağrıyı azaltmada etkili olmuş ve minimal ek analjezi gereksinimi doğmuştur. SCPB ile ilgili herhangi bir komplikasyon gözlenmemiştir. SCPB, supraglottik larenjektomi ve bilateral boyun diseksiyonu geçiren hastalarda etkili postoperatif ağrı yönetimi sağlamaktadır ve güvenli bir profil sunmaktadır. Ancak, bu bulguların doğrulanması için daha büyük hasta grupları ve karşılaştırma gruplarını içeren çalışmalar gerekmektedir.

**Anahtar kelimeler:** Baş ve boyun cerrahisi, rejyonel anestezi, servikal pleksus bloğu, trakeostomi



**Address for Correspondence:** Engin İhsan Turan, University of Health Sciences Turkey, İstanbul Kanuni Sultan Süleyman Training and Research Hospital, Clinic of Anesthesiology and Reanimation, İstanbul, Turkey

**E-mail:** enginihsan@hotmail.com **ORCID:** orcid.org/0000-0001-7447-5074 **Received:** 05.07.2024 **Accepted:** 25.09.2024

**Cite this article as:** Sarban O, Adıyeke Ö, Mendeş E, Turan Eİ, Gümüş Özcan F. Superficial Cervical Plexus Block for Postoperative Pain Management in Patients Undergoing Supraglottic Laryngectomy and Bilateral Neck Dissection: A Case Series. Bagcilar Med Bull. 2024;9(4):293-296



©Copyright 2024 by the Health Sciences University Turkey, İstanbul Bagcilar Training and Research Hospital. Bagcilar Medical Bulletin published by Galenos Publishing House. Licensed under a Creative Commons Attribution-NonCommercial-NoDerivatives 4.0 (CC BY-NC-ND) International License.

## Introduction

Superficial cervical plexus block (SCPB) is a safe and useful alternative to general endotracheal anesthesia for surgery of the neck, upper shoulder, and occipital scalp area (1,2). Over the subsequent years, it has become a widely used technique in the anesthesia and analgesia management of head and neck surgeries (3). In this letter, we aim to share our experience with SCPB for analgesia management in 10 patients who underwent supraglottic laryngectomy, bilateral neck dissection, and tracheostomy due to laryngeal carcinoma.

## Case Report

Between January 15, 2023, and March 15, 2023, SCPB was administered to 10 patients aged over 18 years with an American Society of Anesthesiologists score of 2 or 3, who underwent supraglottic laryngectomy, bilateral neck dissection, and tracheostomy (Table 1). The indication for surgery in all cases was laryngeal carcinoma, which necessitated the removal of the supraglottic structures, comprehensive neck dissection to address lymphatic spread, and the establishment of a secure airway via tracheostomy. Written informed consent was obtained from all patients.

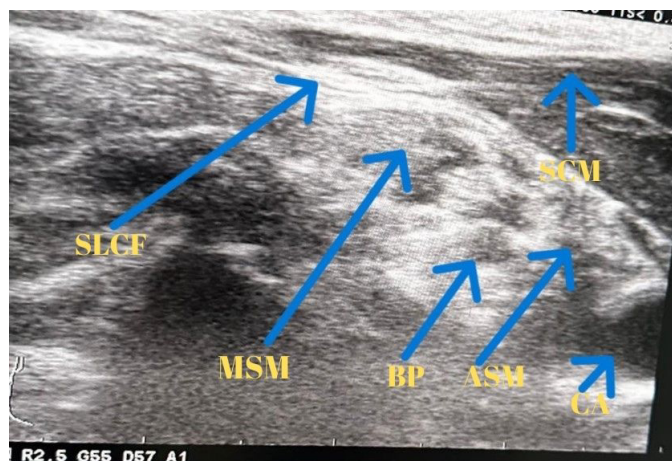
The blocks were performed in the anesthesia preparation room with the patients under routine monitoring. After administering 0.02 mg/kg midazolam, a high-frequency (12-15 MHz) linear ultrasonography (USG) probe (Hitachi Arietta 65 ultrasound device) was placed transversely at the mid-point of the sternocleidomastoid muscle at the cricoid level. Using the in-plane technique, the prevertebral fascia deep to the sternocleidomastoid muscle was visualized (Figure 1). Following negative aspiration, 0.1 mL/kg of 0.25% bupivacaine was administered with USG guidance to ensure the spread of the local anesthetic (4). The procedure was repeated on the contralateral side. No complications related to the procedure were observed. Importantly, in the bilaterally applied block, the phrenic nerve is preserved,

which reduces the risk of diaphragmatic dysfunction and associated respiratory complications.

Each patient received a routine premedication of 2 mg intravenous midazolam. This was followed by 1 mcg/kg fentanyl, 2-3 mg/kg propofol, and 0.6-0.8 mg/kg rocuronium administered intravenously. Maintenance anesthesia was provided with 2% sevoflurane in a mixture of air and oxygen, along with 0.05-0.2 mcg/kg/min intravenous remifentanyl infusion.

Routine anesthesia induction and orotracheal intubation were performed. Radial artery cannulation was done for monitoring. At the end of the uncomplicated surgeries, patients received 1 g paracetamol and 100 mg tramadol for analgesia and were extubated with sugammadex. They were then transferred to the intensive care unit (ICU) with tracheostomy, conscious, and breathing spontaneously with 4 L/min oxygen support.

Postoperatively, 1 g of paracetamol was administered at 8, 16, and 24 hours. Pain scores, measured using the numeric rating scale (NRS), are summarized in Table 1. One patient



**Figure 1.** Ultrasonographic view of superficial cervical plexus

SLCF: Superficial layer of cervical fascia, MSM: Middle scalene muscle, ASM: Anterior scalene muscle, CA: Carotis artery, BP: Brachial plexus, SCM: Sternocleidomastoid muscle

**Table 1. Demographical data of the patients**

	Case 1	Case 2	Case 3	Case 4	Case 5	Case 6	Case 7	Case 8	Case 9	Case 10
<b>Age</b>	53	62	61	71	68	59	64	62	57	55
<b>Gender</b>	M	F	M	M	M	F	M	M	F	M
<b>BMI</b>	28.1	27.7	22.5	23.9	28.2	29.7	24.1	23.4	28.6	27.9
<b>Comorbidities</b>	0	DM, HT	HT, CAD	DM, HT, KKY	HT	DM, HT	HT	0	HT	0

BMI: Body mass index, DM: Diabetes mellitus, CAD: Coronary artery disease, HT: Hypertension

**Table 2. Postoperative pain and coughing scores (NRS)**

	Case 1	Case 2	Case 3	Case 4	Case 5	Case 6	Case 7	Case 8	Case 9	Case 10	Average
1 <sup>st</sup> hour	2	1	1	1	3	3	1	2	1	1	1.6
6 <sup>th</sup> hour	1	2	1	1	6	4	1	2	3	2	2.3
12 <sup>th</sup> hour	3	2	3	2	2	3	2	2	2	3	2.4
24 <sup>th</sup> hour	3	2	2	1	3	3	3	1	3	3	2.4
Coughing	1	3	2	3	4	1	2	1	2	2	2.1

NRS: Numeric rating scale

with an NRS score of 4 received 75 mg intramuscular diclofenac sodium, and another with an NRS score of 6 received 4 mg intravenous morphine hydrochloride. All patients were transferred to the ward after a 24-hour ICU stay.

The average NRS scores at different postoperative times were as follows; 1 hour: 1.6, 6 hours: 2.3, 12 hours: 2.4, 24 hours: 2.4 (Table 2).

## Discussion

Our findings demonstrate that the use of SCPB in patients undergoing supraglottic laryngectomy and bilateral neck dissection for laryngeal carcinoma effectively reduces postoperative pain levels. The average NRS scores at 24 hours follow-up were relatively low, indicating good pain control.

It is important to note that, to the best of our knowledge, this case series represents the only report in the literature that examines the use of SCPB specifically for patients undergoing supraglottic laryngectomy, bilateral neck dissection, and tracheostomy. There are no previous studies that have focused on the efficacy of SCPB in this specific surgical context. However, SCPB has been studied in other types of head and neck surgeries, such as thyroid surgery, where it has been shown to be effective for analgesia. For instance, a systematic review and meta-analysis by Wilson et al. (5) demonstrated the analgesic effects of bilateral SCPB in thyroid surgery, highlighting its potential to reduce pain with a favorable safety profile.

The advantages of SCPB include its ability to provide targeted pain relief without the systemic side effects associated with opioids. This is particularly beneficial in head and neck surgeries where opioid-induced respiratory depression can complicate recovery, especially in patients with a tracheostomy.

Moreover, SCPB was associated with minimal complications in our case series, highlighting its safety profile. The use of

USG ensured accurate placement of the local anesthetic, which likely contributed to the efficacy and safety observed.

This study has several limitations. Firstly, the absence of patient-controlled analgesia (PCA) devices in the postoperative pain management protocol may have limited the ability to accurately assess opioid consumption, as PCA allows for precise tracking of opioid usage and provides more personalized pain control. Secondly, the study lacked a comparison group, which restricts the ability to draw definitive conclusions about the efficacy of SCPB relative to other analgesic methods. Lastly, the small sample size of only 10 patients reduces the generalizability of the findings. Future studies with larger sample sizes, comparison groups, and the inclusion of PCA devices are needed to provide more robust evidence for the use of SCPB in this surgical context.

## Conclusion

In conclusion, SCPB provides effective postoperative pain management for patients undergoing supraglottic laryngectomy and bilateral neck dissection, offering a viable alternative to opioid-based analgesia.

## Ethics

## Footnotes

## Authorship Contributions

Surgical and Medical Practices: O.S., Ö.A., E.M., F.G.Ö., Concept: O.S., Ö.A., E.M., F.G.Ö., Design: O.S., Ö.A., E.M., F.G.Ö., Data Collection or Processing: O.S., Ö.A., E.M., E.İ.T., F.G.Ö., Analysis or Interpretation: O.S., Ö.A., E.M., E.İ.T., F.G.Ö., Literature Search: O.S., Ö.A., E.M., E.İ.T., F.G.Ö., Writing: O.S., Ö.A., E.M., E.İ.T., F.G.Ö.

**Conflict of Interest:** No conflict of interest was declared by the authors.

**Financial Disclosure:** The authors declared that this study received no financial support.

## References

1. Masters RD, Castresana EJ, Castresana MR. Superficial and deep cervical plexus block: technical considerations. *AANA J*. 1995;63(3):235-243.
2. Davies MJ, Murrell GC, Cronin KD, Meads AC, Dawson A. Carotid endarterectomy under cervical plexus block--a prospective clinical audit. *Anaesth Intensive Care*. 1990;18(2):219-223.
3. Kim JS, Ko JS, Bang S, Kim H, Lee SY. Cervical plexus block. *Korean J Anesthesiol*. 2018;71(4):274-288.
4. Stoeter D. Superficial (and Intermediate) cervical plexus block. ESPA. Available from: <https://www.euroespa.com/science-education/specialized-sections/espa-pain-committee/us-regional-anaesthesia/head-and-neck/superficial-cervical-plexusblock/>.
5. Wilson L, Malhotra R, Mayhew D, Banerjee A. The analgesic effects of bilateral superficial cervical plexus block in thyroid surgery: A systematic review and meta-analysis. *Indian J Anaesth*. 2023;67(7):579-589.