

# De Novo Triple Negative Breast Cancer Development in a Patient Who had Lipofilling for Esthetic Reasons

## Estetik Nedeniyle Lipofilling Yapılan Hastada De Novo Üçlü Negatif Meme Kanseri Gelişimi

✉ Nihan Turhan<sup>1</sup>, ✉ Osman Cem Yılmaz<sup>2</sup>

<sup>1</sup>University of Health Sciences Turkey, Sancaktepe Şehit Prof. Dr. İlhan Varank Training and Research Hospital, Clinic of General Surgery, İstanbul, Turkey

<sup>1</sup>Istanbul Breast Center, Clinic of General Surgery, İstanbul, Turkey

### Abstract

Lipofilling has gained increased confidence in both esthetic and reconstructive breast surgery. However, in breast carcinoma patients there are some doubts about the crosstalk between adipose tissue microenvironment and cancer tissue. In our case report, a 48-year-old female patient with a heterozygous pathogenic variant in the chromosome 17 *BRCA 1* gene had a history of lipofilling after loss of breast prosthesis. The patient presented with the development of triple negative breast carcinoma 20 months after lipofilling application. This case again raises the question about the risk of lipofilling on breast cancer development.

**Keywords:** Adipose tissue, breast cancer, lipofilling

### Öz

Lipofilling uygulaması hem estetik hem de rekonstrüktif meme cerrahisinde güvenilirlik kazanmıştır. Ancak meme kanseri hastalarında yağ dokusu mikro çevresi ile kanser dokusu arasında oluşabilecek etkileşim konusunda bazı şüpheler vardır. Olgu sunumumuzda kromozom 17 *BRCA 1* geninde heterozigot patojenik varyant bulunan 48 yaşındaki kadın hastanın meme protezi kaybı sonrası lipofilling öyküsü mevcuttu. Hasta lipofilling uygulamasından 20 ay sonra üçlü negatif meme kanseri gelişimi ile başvurdu. Bu durum lipofilling işlemi sonrası meme kanseri risk artışına ilişkin soruları bir kez daha gündeme getirmektedir.

**Anahtar kelimeler:** Lipofilling, meme kanseri, yağ dokusu

### Introduction

Lipofilling has gained popularity in breast surgery for esthetic and reconstructive purposes. It is efficient to correct volume defects with minimal scarring, improve esthetic results and lead to increase in patient satisfaction rate (1,2). On the other hand, the oncologic safety of lipofilling in the context of breast reconstruction is still a matter of controversy (3). Adipose tissue is a rich source of adipose tissue derived stem cells and growth factors. As a result of

lipofilling, inflammation and remodeling processes occur at the recipient tissue. Up to now, it remains unclear whether this adipose tissue-breast cancer interactions really have the ability to stimulate breast cancer progression. A careful oncological follow-up is recommended for breast cancer patients after lipofilling (4,5).

In this article, we presented a case of a 48-year-old woman with triple negative breast cancer development in the left breast 20 months after lipofilling for esthetic reasons.



**Address for Correspondence:** Nihan Turan, University of Health Sciences Turkey, Sancaktepe Şehit Prof. Dr. İlhan Varank Training and Research Hospital, Clinic of General Surgery, İstanbul, Turkey

**E-mail:** drnihanturhan@yahoo.com **ORCID:** orcid.org/0000-0002-8672-3853 **Received:** 23.01.2024 **Accepted:** 03.03.2024

**Cite this article as:** Turhan N, Yılmaz OC. De Novo Triple Negative Breast Cancer Development in a Patient Who had Lipofilling for Esthetic Reasons. Bagcilar Med Bull 2024;9(2):147-150



©Copyright 2024 by the Health Sciences University Turkey, İstanbul Bagcilar Training and Research Hospital. Bagcilar Medical Bulletin published by Galenos Publishing House. Licensed under a Creative Commons Attribution-NonCommercial-NoDerivatives 4.0 (CC BY-NC-ND) International License.

## Case Report

A 48-year-old female patient applied to our clinic with a complaint of a palpable mass in her left breast.

On the physical examination of the patient, a hard mass of approximately 3 cm in the upper inner quadrant and widespread nodular lesions in the left breast were detected. No lymphadenopathy was present in the bilateral axilla.

Particularly in the patient's medical history, she had bilateral augmentation mammoplasty surgery with breast implants in 1997. There was replacement of the left-side implant in 2012 due to implant complications. Removal of the left implant and lipofilling was done in January 2021. Breast ultrasound and magnetic resonance imaging scans performed at that time showed no suspicious findings for cancer in either breast.

The patient complained of palpable hardness in the left breast after six months after fat injection. The mammographic evaluation was consistent with fat necrosis in the middle inner quadrant of the left breast and superimposed on the pectoral muscle in the deep plane.

She noticed increase in the size of the mass in the left breast after one year. In the radiological evaluation performed in August 2022, there was a 27\*16 mm sized, BIRADS 5 solid mass lesion in the upper inner quadrant of the left breast and lymphadenopathy, the largest of which was 19 mm in diameter and showed cortical thickening (5.5 mm) detected in the axilla (Figures 1, 2).

Tru-cut biopsy results from the patient's mass in the left breast were invasive breast carcinoma, grade 3, ER-, PR-, HER2-, Ki-67; 60-70%. The pathology results from the axillary lymph nodes were benign.

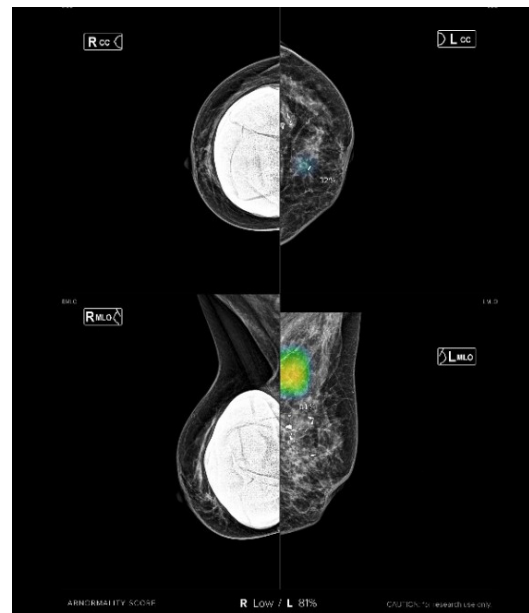
In genetic testing, a heterozygous pathogenic variant was detected in the chromosome 17 *BRCA 1* gene (c.66dup-pGlu23Argfrester18). In her family history, her aunt had colectomy for colon carcinoma.

With those findings, the patient was evaluated at the oncology council and the patient underwent neoadjuvant chemotherapy. After chemotherapy, a radiological complete response was detected in the mass.

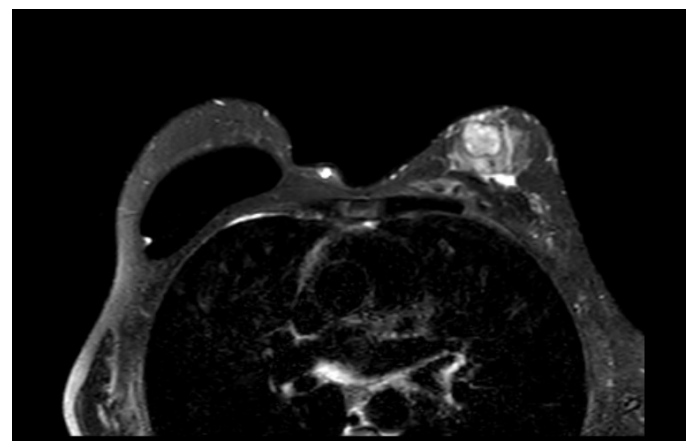
In May 2023, nipple skin sparing mastectomy, axillary sentinel lymph node sampling and breast reconstruction was performed for the left breast. The pathology results of the patient revealed no residual invasive carcinoma (complete response), and no metastasis in the axillary lymph nodes (0/4).

## Discussion

Lipofilling has been used in the last century for filling defects and remodeling body shape. It is an extremely useful technique in esthetic and reconstructive breast surgery as well. The multipotent stem cells found in adipose tissue has regenerative potential. Patients are more satisfied with the appearance of their breast and showed an improved psychosocial, sexual, and physical well-being after breast surgery. They also have significantly lower implant complications, capsular contracture rate, and



**Figure 1.** Malignant-looking mass in the left breast confirmed by artificial intelligence application in mammography



**Figure 2.** Breast MRI shows a well-circumscribed heterogeneous contrast-enhancing lesion in the upper inner quadrant of the left breast and prosthesis in right breast

MRI: Magnetic resonance imaging

breast pain as a result of the regenerative potential of the fat tissue (1,2,6). In the previous studies conducted on healthy BRCA mutation carriers, lipofilling was regarded as an oncologically safe method after prophylactic mastectomy (7,8).

However, fat tissue with its stem cells, adipokines and vascular-inducing factors may have pro-tumorigenic potential. Crosstalk between this mesenchymal stem cells and epithelial cells have the ability to participate in primary and metastatic tumor development and progression (9,10). A remarkable role of adipose tissues in cancer development as increased breast cancer proliferation and enhanced agresiveness was shown in animal and *in vitro* studies (2,11-13). On the other hand, there were no clearly demonstrated cancer recurrence risk increase in clinical studies (5,14). One of the rare clinical studies showing an increased local event risk was reported by Petit et al. (4). They showed increased intraepithelial neoplasia risk. They took attention to increased risk of local recurrence in women <50 years, with high grade neoplasia, Ki-67  $\geq$ 14 who had undergone quadrantectomy. They reported that cancer recurrence happened generally three to four years after lipofilling (4). Similarly, Berti et al. (15) conducted a retrospective study on breast carcinoma patients and compared survival and local recurrence rates between patients with lipofilling and without lipofilling. They showed that, lipofilling was an independent predictive factor for local recurrence in invasive breast carcinoma patients (15).

The risk of inducing *de novo* carcinogenesis after lipofilling is a very rare circumstance. Cheng et al. (16) presented a case with musinous carcinoma, discovered 2 months after lipofilling. As invasive breast carcinoma development from carcinoma *in situ* was 3-5 years according to the literature, they took attention to the short time interval after lipofilling to breast carcinoma development (16).

## Conclusion

In our case report, we presented a patient being BRCA1 heterozygous positive and *de novo* development of triple negative breast carcinoma shortly after fat injection. Although previous studies have reported that lipofilling is generally safe even in patients with BRCA mutation, we would like to emphasize once again that caution should be exercised in these procedures.

## Ethics

**Informed Consent:** Written informed consent was obtained from the patient for the publication of this case report and accompanying images.

## Authorship Contributions

Concept: N.T., Design: N.T., Data Collection or Processing: N.T., Analysis or Interpretation: N.T., O.C.Y., Drafting Manuscript: N.T., Critical Revision of Manuscript: N.T., O.C.Y., Final Approval and Accountability: N.T., O.C.Y., Technical or Material Support: N.T., O.C.Y., Supervision: N.T., O.C.Y., Writing: N.T., O.C.Y.

**Conflict of Interest:** No conflict of interest was declared by the authors.

**Financial Disclosure:** The authors declared that this study received no financial support.

## References

1. Andrews G, Ahsan MD, Tabrizi AR, Razzouk K, Fitoussi A. Long term surgical outcome of lipofilling based Breast reconstruction after mastectomy and radiotherapy: Clinical retrospective Descriptive study. *EJSO* 2021;47(2):e44-e45.
2. Bayram Y, Sezgic M, Karakol P, Bozkurt M, Filinte GT. The use of autologous fat grafts in breast surgery: A literature review. *Arch Plast Surg* 2019;46(6):498-510.
3. Cohen S, Sekigami Y, Schwartz T, Losken A, Margenthaler J, Chatterjee A. Lipofilling after breast conserving surgery: a comprehensive literature review investigating its oncologic safety. *Gland Surg.* 2019;8(5):569-580.
4. Petit JY, Rietjens M, Botteri E, Rotmensz N, Bertolini F, Curigliano G, et al. Evaluation of fat grafting safety in patients with intraepithelial neoplasia: a matched-cohort study. *Ann Oncol* 2013;24(6):1479-1484.
5. Wazir U, El Hage Chehade H, Heaton H, Oteifa M, Kasem A, Mokbel K. Oncological Safety of Lipofilling in Patients with Breast Cancer: A Meta-analysis and Update on Clinical Practice. *Anticancer Res* 2016;36(9):4521-4528.
6. Ribuffo D, Atzeni M, Guerra M, Bucher S, Politi C, Deidda M, et al. Treatment of irradiated expanders: protective lipofilling allows immediate prosthetic breast reconstruction in the setting of postoperative radiotherapy. *Aesthetic Plast Surg* 2013;37(6):1146-1152.
7. Ho Quoc C, Dias LPN, Braghiroli OFM, Martella N, Giovinazzo V, Piat JM. Oncological Safety of Lipofilling in Healthy BRCA Carriers After Bilateral Prophylactic Mastectomy: A Case Series. *Eur J Breast Health* 2019;15(4):217-221.
8. Kronowitz SJ, Mandujano CC, Liu J, Kuerer HM, Smith B, Garvey P, et al. Lipofilling of the Breast Does Not Increase the Risk of Recurrence of Breast Cancer: A Matched Controlled Study. *Plast Reconstr Surg* 2016;137(2):385-393.

9. Vona-Davis L, Rose DP. Adipokines as endocrine, paracrine, and autocrine factors in breast cancer risk and progression. *Endocr Relat Cancer* 2007;14(2):189-206.
10. Piccotti F, Rybinska I, Scoccia E, Morasso C, Ricciardi A, Signati L, et al. Lipofilling in Breast Oncological Surgery: A Safe Opportunity or Risk for Cancer Recurrence? *Int J Mol Sci* 2021;22(7):3737.
11. Rowan BG, Gimble JM, Sheng M, Anbalagan M, Jones RK, Frazier TP, et al. Human adipose tissue-derived stromal/stem cells promote migration and early metastasis of triple negative breast cancer xenografts. *PLoS One* 2014;9(2):e89595.
12. Massa M, Gasparini S, Baldelli I, Scarabelli L, Santi P, Quarto R, et al. Interaction Between Breast Cancer Cells and Adipose Tissue Cells Derived from Fat Grafting. *Aesthet Surg J* 2016;36(3):358-363.
13. Xu H, Li W, Luo S, Yuan J, Hao L. Adipose derived stem cells promote tumor metastasis in breast Cancer cells by stem cell factor inhibition of miR20b. *Cell Signal* 2019;62:109350.
14. Krastev T, van Turnhout A, Vriens E, Smits L, van der Hulst R. Long-term Follow-up of Autologous Fat Transfer vs Conventional Breast Reconstruction and Association With Cancer Relapse in Patients With Breast Cancer. *JAMA Surg* 2019;154(1):56-63.
15. Berti M, Goupille C, Doucet M, Arbion F, Vilde A, Body G, et al. Oncological Safety of Autologous Fat Grafting in Breast Reconstruction after Mastectomy for cancer: A case-control study. *J Gynecol Obstet Hum Reprod* 2022;51(1):102257.
16. Cheng L, Han XF, Zhang C, Lv LL, Li FC. Occurrence of Breast Mucinous Carcinoma After Autologous Fat Grafting for Breast Augmentation. *Aesthetic Plast Surg* 2016;40(1):102-105.