

Uterine Rupture: Fifteen Weeks of Non-communicating Uterine Horn Pregnancy

Uterin Rüptür: On Beş Haftalık Rüptüre Non-komünikan Rudimenter Horn Gebelik

Ömer Faruk Bayraktar, Sevde Nur Su, Tolga Karacan, Hakan Güraslan

University of Health Sciences Turkey, İstanbul Bağcılar Training and Research Hospital, Clinic of Obstetrics and Gynecology, İstanbul, Turkey

Abstract

We evaluated the management of a ruptured non-communicated rudimentary horn pregnancy at the 15th gestational week. A 22-year-old multigravida who was detected to have a 15-week pregnancy according to her last menstrual period was admitted to our clinic with abdominal pain. As the uterine cavity was imaged in 30 mm on transvaginal ultrasonography and front of the uterus 15-week-old fetus without cardiac activity, emergency laparotomy was performed with the possible diagnosis of uterine rupture. Diagnosis of rudimentary uterine horn pregnancy is challenging; thus, it can be encountered with the clinical picture of uterine rupture in later weeks of pregnancy. The most appropriate treatment in such patients is excision of the uterine horn.

Keywords: Müllerian ducts, pelvic pain, uterine rupture

Öz

Rüptüre olmuş 15 hafta non-komünike rudimenter uterin horn gebeliğinin takip ve tedavisinde izlenmesi gereken yolu değerlendirdik. Yirmi iki yaşında gravida üç bir normal doğum bir abortusu olan son adet tarihine göre 15 hafta 4 günlük gebeliği olduğu tespit edilen hasta, kliniğimize karın ağrısı tablosu ile geldi. Transvajinal ultrasonda uterin kavitenin 30 mm düzensiz olması ve uterus önünde 12+5 hafta ölçülerinde kalp atışı olmayan fetus tespit edilmesi üzerine uterin rüptür düşünülerek acil laparotomi yapıldı. Rudimenter horn gebeliğinin tanısı koymak zordur. Bu nedenle ilerleyen gebelik haftalarında karşımıza rüptür ile gelebilir. Böyle bir hastada en uygun yaklaşım non-komünike uterin hornu eksize etmektir.

Anahtar kelimeler: Müllerian kanallar, pelvik ağrı, uterin rüptür

Introduction

Müllerian agenesis or hypoplasia can lead to variable uterine development and congenital absence of the vagina, known as Mayer-Rokitansky-Küster-Hauser syndrome. The resulting uterus can be a lateral hemi-uterus, uterine horns (e.g., unicornuate uterus), or a midline uterus without a cervix (it may most commonly fail to develop).

Lateral fusion defects lead to the development of symmetric or asymmetric organs (e.g., bicornuate uterus, uterus didelphys). Vertical fusion defects result in transverse vaginal septum, segmental vaginal agenesis, and/or cervical agenesis or dysgenesis (1,2).

Non-pregnant women present with symptoms such as hematometra, hematocolpos, retrograde menstruation, and endometriosis, causing pelvic pain. In pregnant patients, it manifests with symptoms such as recurrent miscarriages, preterm birth, intrauterine growth restriction, cervical insufficiency, fetal malpresentation, and rupture of the rudimentary horn (3,4).

Clinically, uterine rupture often presents as an acute abdominal emergency with intra-abdominal hemorrhage. Uterine rupture is an obstetric emergency that leads to maternal and fetal mortality and morbidity (5). Most reported cases in the literature are associated with scarred



Address for Correspondence: Ömer Faruk Bayraktar, University of Health Sciences Turkey, İstanbul Bağcılar Training and Research Hospital, Clinic of Obstetrics and Gynecology, İstanbul, Turkey

E-mail: ofbayraktar@icloud.com **ORCID:** orcid.org/0009-0002-2142-362X **Received:** 29.10.2023 **Accepted:** 26.01.2024

Cite this article as: Bayraktar ÖF, Su SN, Karacan T, Güraslan H. Uterine Rupture: Fifteen Weeks of Non-communicating Uterine Horn Pregnancy. Bagcilar Med Bull 2024;9(2):139-142



©Copyright 2024 by the Health Sciences University Turkey, İstanbul Bağcılar Training and Research Hospital. Bagcilar Medical Bulletin published by Galenos Publishing House. Licensed under a Creative Commons Attribution-NonCommercial-NoDerivatives 4.0 (CC BY-NC-ND) International License.

uterine rupture (6). Other predisposing factors, as in our case, include uterine anomalies. In this study, we identified a ruptured non-communicating rudimentary horn in a 16-week multigravida with a pre-diagnosis of uterine rupture. The thin myometrial layer in the rudimentary horn, as in this case, increases the likelihood of rupture.

Case Report

A 22-year-old patient with a history of one normal delivery and one abortion at 15 weeks presented to our clinic with widespread abdominal pain. Pelvic examination revealed cervical tenderness. Abdominal examination revealed signs of guarding and rebound tenderness. Arterial blood pressure was measured at 70/50 mmHg, and the pulse rate was 140 beats/min. Transvaginal ultrasound showed widespread free fluid in the pouch of Douglas, a 30-mm-thick fluid collection in the endometrium, and a fetus without cardiac activity at 12 weeks and 5 days in the anterior part of the uterus. Abdominal ultrasound revealed widespread free fluid in the liver and spleen. The preoperative hemoglobin level was measured at 6.5 g/dL. The patient underwent emergency laparotomy with a pre-diagnosis of uterine rupture. A midline incision was made to enter the abdomen. Rupture was observed in the right cornua region (Figure 1). Fetal observation was made in the abdominal

cavity (Figure 2). Placental fragments were observed in the cornua (Figure 3) and excised. Approximately 3000 cc of hemorrhagic fluid was aspirated from the abdomen. The uterus, both ovaries, and fallopian tubes were intact. A 200-g dead fetus and placenta were removed from the abdomen. After hemostasis was achieved, the uterine horn was excised. The abdomen was closed. Subsequently, proper endometrial curettage was performed using a number 10 Karman cannula. After achieving hemostasis, the operation was concluded.

Discussion

Müllerian agenesis/hypoplasia can lead to the development of congenital anomalies in the uterus, hymen, or vagina (e.g., unicornuate uterus), whereas fusion defects can result in the formation of uterus didelphys, bicornuate uterus, and/or vaginal septum. Additionally, in patients with Müllerian anomalies, 20% to 30% of them have kidney anomalies (7). These conditions commonly lead to gynecological complaints such as dysmenorrhea, dyspareunia, endometriosis, and infertility. Hematometra can develop in a rudimentary horn, which can be mistaken for a pelvic mass. Endometriosis can occur because of retrograde

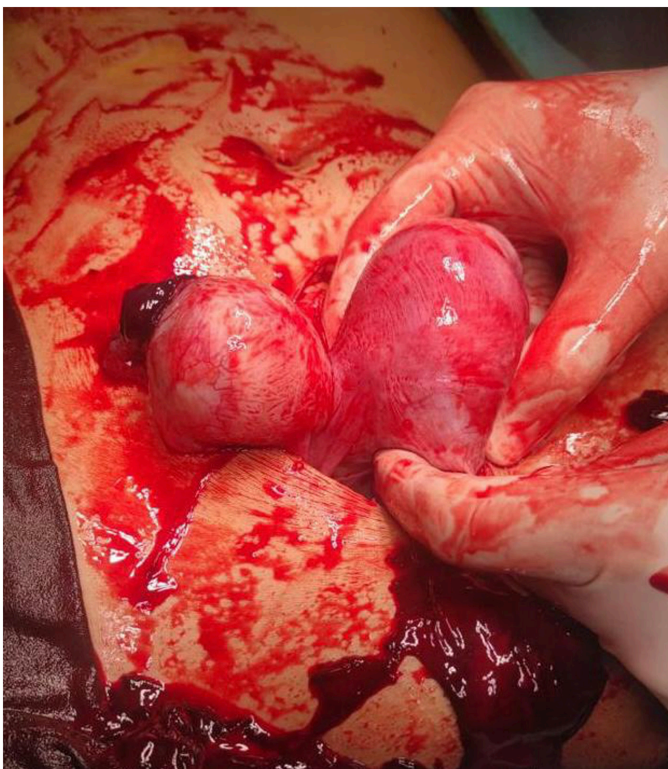

Figure 1. Ruptured uterine horn

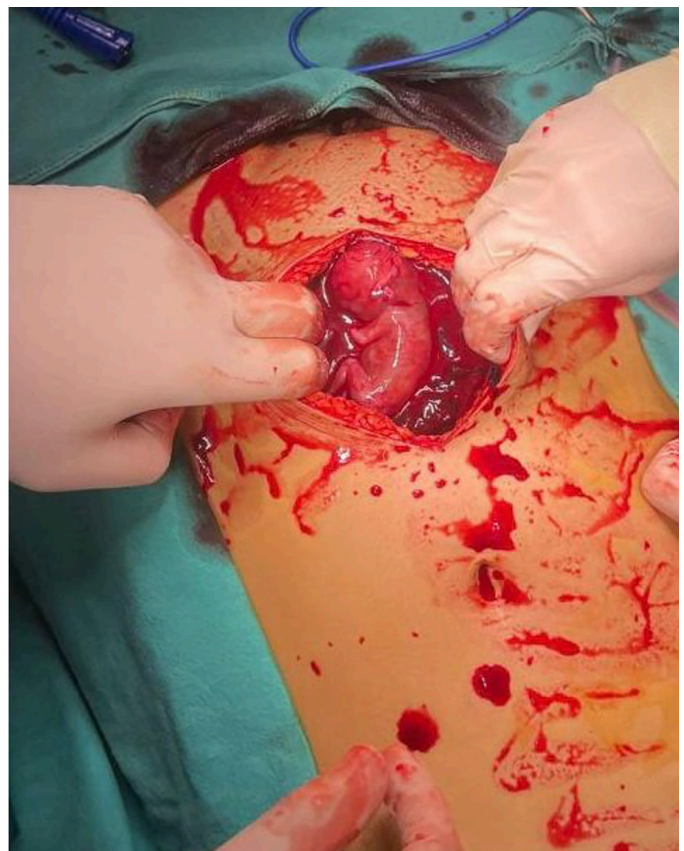


Figure 2. Fetus in the abdominal cavity

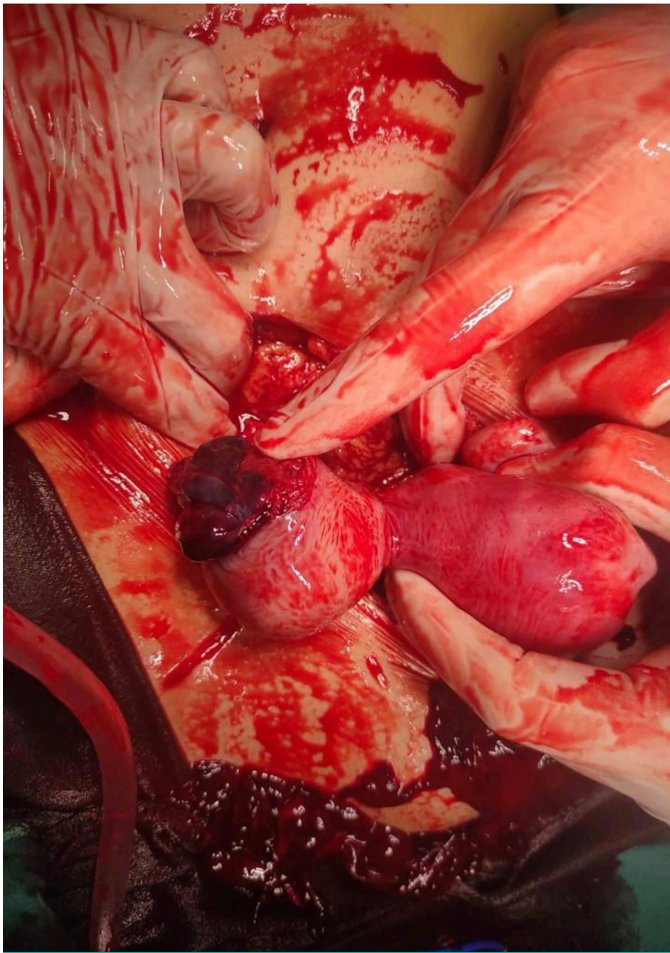


Figure 3. Right cornual region ruptured

menstruation. Patients with extensive endometriosis may present with infertility. In pregnant women, symptoms may include hypertension, recurrent miscarriages, preterm birth, postpartum bleeding, intrauterine growth restriction, fetal malpresentation, cervical insufficiency, placental invasion abnormalities, and uterine rupture. The vaginal septum can be a reason for cesarean section. Postpartum bleeding can occur because of placental attachment to the accessory part of the uterus. Pregnancy-induced hypertension has been associated with concomitant congenital renal anomalies (8).

The formation of non-communicating rudimentary horn pregnancies remains a subject of debate. Sperm migrate to the rudimentary horn through transperitoneal migration. This condition is associated with spontaneous abortion, preterm birth, intrauterine growth restriction, intraperitoneal hemorrhage, and uterine rupture. Because the myometrial layer is thin in the rudimentary horn, the risk of uterine rupture increases as the gestational weeks

progress. Typically, uterine horn pregnancies present with rupture in the second trimester. Rare cases of term horn pregnancies have also been reported.

In non-communicating uterine horn pregnancies, high alpha-fetoprotein levels and abnormal uterine artery Doppler indices on ultrasonographic examination during second trimester screening have been reported (9).

In early-week ultrasonographic examinations, two separate endometrial linings were observed within two adjacent masses. However, as pregnancy progresses, the growth of the uterus carrying the fetus will obscure the other uterus, making the diagnosis more challenging. In this study, early diagnosis was not possible because of the absence of antenatal follow-up. Rudimentary horn excision was performed in our patient with fertility expectations. In the future, if pregnancy is not desired, hysterectomy can be performed to eliminate the risk of ectopic pregnancy. For patients with no fertility expectations who wish to menstruate, excision of the rudimentary horn with tubal ligation is a treatment option. Follow-up of the patient is necessary in the advanced stages for early detection of implantation in early pregnancy. In addition, precautions should be taken to reduce the risk of premature birth.

In conclusion, in rudimentary horn pregnancies, clinical suspicion, early diagnosis, and timely laparotomy can reduce maternal and perinatal mortality and morbidity. However, in recent years, a conservative approach has been advocated in well-informed, highly selective cases with sufficient myometrial thickness (10).

Ethics

Informed Consent: The patient's consent was obtained for this case report.

Authorship Contributions

Concept: T.K., S.N.S., Design: T.K., S.N.S., Data Collection or Processing: Ö.F.B., S.N.S., Analysis or Interpretation: Ö.F.B., S.N.S., Drafting Manuscript: Ö.F.B., S.N.S., Critical Revision of Manuscript: T.K., H.G., Final Approval and Accountability: T.K., H.G., Technical and Material Support: T.K., H.G., Supervision: H.G., Writing: Ö.F.B.

Conflict of Interest: No conflict of interest was declared by the authors.

Financial Disclosure: The authors declared that this study received no financial support.

References

1. Fontana L, Gentilin B, Fedele L, Gervasini C, Miozzo M. Genetics of Mayer-Rokitansky-Küster-Hauser (MRKH) syndrome. *Clin Genet* 2017;91(2):233-246.
2. Venetis CA, Papadopoulos SP, Campo R, Gordts S, Tarlatzis BC, Grimbizis GF. Clinical implications of congenital uterine anomalies: a meta-analysis of comparative studies. *Reprod Biomed Online* 2014;29(6):665-683.
3. Grimbizis GF, Camus M, Tarlatzis BC, Bontis JN, Devroey P. Clinical implications of uterine malformations and hysteroscopic treatment results. *Hum Reprod Update* 2001;7(2):161-174.
4. Panagiotopoulos M, Tseke P, Michala L. Obstetric Complications in Women With Congenital Uterine Anomalies According to the 2013 European Society of Human Reproduction and Embryology and the European Society for Gynaecological Endoscopy Classification: A Systematic Review and Meta-analysis. *Obstet Gynecol* 2022;139(1):138-148.
5. Chen LH, Tan KH, Yeo GS. A ten-year review of uterine rupture in modern obstetric practice. *Ann Acad Med Singap* 1995;24(6):830-835.
6. Sweeten KM, Graves WK, Athanassiou A. Spontaneous rupture of the unscarred uterus. *Am J Obstet Gynecol* 1995;172(6):1851-1855; discussion 1855-1856.
7. Lin PC, Bhatnagar KP, Nettleton GS, Nakajima ST. Female genital anomalies affecting reproduction. *Fertil Steril* 2002;78(5):899-915.
8. Heinonen PK. Gestational hypertension and preeclampsia associated with unilateral renal agenesis in women with uterine malformations. *Eur J Obstet Gynecol Reprod Biol* 2004;114(1):39-43.
9. Ekin M, Yaşar L, Ertürk D, Özdemir İA, Keven MC. Incomplete rupture of pregnancy in the non-communicating rudimentary uterine horn at 26 weeks gestation, with neonatal and maternal survival. *Turkiye Klinikleri J Gynecol Obst* 2009;19(6):365-367.
10. Nahum GG. Rudimentary uterine horn pregnancy. The 20th-century worldwide experience of 588 cases. *J Reprod Med* 2002;47(2):151-163.