

A Rare Cause of Acute Abdomen in Children: Heterotopic Gastric Mucosa Located in the Ileum Mimicking Intussusception

Çocuklarda Nadir Bir Akut Karın Nedeni: İleumda İnvajinasyonu Taklit Eden Heterotopik Gastrik Mukoza

✉ Mehmet Uysal

Karamanoğlu Mehmetbey University Faculty of Medicine, Department of Pediatric Surgery, Karaman, Turkey

Dear Editor,

Heterotopic gastric mucosa (HGM) is usually a clinically asymptomatic benign lesion. The incidence of this lesion usually diagnosed incidentally is around 2%, and it is more common in the adult population. Congenital remnants of gastric mucosa can be seen anywhere in the gastrointestinal tract (such as the esophagus, duodenum, small intestine, and Meckel's diverticulum), but ileum localization is rare. HGM located in the ileum is usually in the form of a polypoid mass smaller than 1 cm, attached to the intestinal wall on the mesentery surface of the intestine (1).

Although HGM is seen mainly in the esophagus, duodenum, and Meckel's diverticulum, it is rarely in the jejunum and ileum. Most jejunal and ileal HGMs are diagnosed by samples of histological results after surgery. HGM is usually in the form of an entrance patch in the upper 1/3 of the esophagus; It is seen as nodular and jejunal masses in the duodenum and as polypoid masses in the ileum (2).

HGM may be congenital or acquired, but its formation is unknown. Acquired HGM occurs when gastric mucosa epithelium is affected by the effect of inflammatory or peptic processes. HGM is usually clinically silent and does not require treatment; however, surgical intervention

may be required after complications such as bleeding and intestinal obstruction. Therefore, HGM of the ileum is extremely rare. Diagnosis of ileal polypoid lesions is important in affecting gastric mucosal epithelium (3).

In this study (patient informed consent form was obtained), a ten-year-old girl with complaints of abdominal pain and vomiting referred to our clinic with a preliminary diagnosis of intussusception as a result of ultrasonography (US) performed in a private medical center. When he applied to our clinic, the patient did not have acute abdomen findings in the examination and did not have a palpable mass. Her complaints of pain regressed and his vomiting stopped. In the standing direct abdominal X-ray (Figure 1), air-fluid levels, which is the radiological finding of intestinal obstruction, and on repeated US a 10 cm long intussusception image extending from the lower quadrant of the abdomen to the left upper side was observed. In the examination performed proximally from the ileocecal valve in the patient who was taken into surgery, no other obvious pathology was observed in the small bowel serosa.

The mucosal lesion in the sessile polyp structure was excised within the invaginated segment approximately



Address for Correspondence: Mehmet Uysal, Karamanoğlu Mehmetbey University Faculty of Medicine, Department of Pediatric Surgery, Karaman, Turkey

E-mail: drmyzuysal@kmu.edu.tr **ORCID ID:** orcid.org/0000-0003-1561-6601 **Received:** 19.05.2023 **Accepted:** 05.08.2023

Cite this article as: Uysal M. A Rare Cause of Acute Abdomen in Children: Heterotopic Gastric Mucosa Located in the Ileum Mimicking Intussusception. Bagcilar Med Bull 2023;7(4):400-401



©Copyright 2023 by the University of Health Sciences Turkey, Istanbul Bağcilar Training and Research Hospital. Bagcilar Medical Bulletin published by Galenos Publishing House. Licensed under a Creative Commons Attribution-NonCommercial-NoDerivatives 4.0 (CC BY-NC-ND) International License.

40 cm proximal to the ileocecal valve, located on the mesenteric side and continuing for about 10 cm, leaving intact intestinal margins. Intestinal continuity was achieved with primary anastomosis. The patient, who was fed orally on the third postoperative day, was discharged on the fifth day. Its pathology was reported as polypoid gastric heterotopia (Figure 2). The patient is followed up in the 2nd postoperative month without any complaints.

In conclusion, although HGM is asymptomatic, they can sometimes present with symptoms suggestive of acute abdomen, as in our case. Although rare, HGM should be kept in mind in such cases. This case was diagnosed as “polypoid gastric heterotype” postoperatively and presented as a rare cause of acute abdomen.

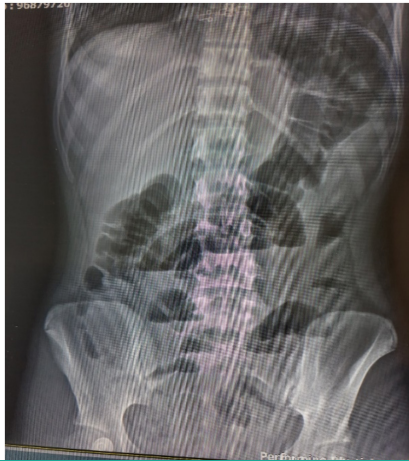

Figure 1. In the standind direct abdominal X-ray, air-fluid levels, which is the radiological finding of ileus

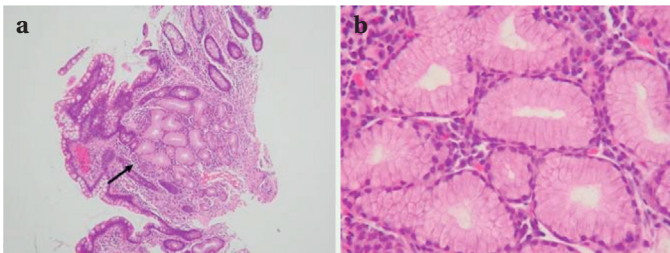


Figure 2. A heterotopic diagnosis. gastric mucosa of the ileum (HGM).

Lesions showing images obtained with hematoxylin and eosin of biopsy specimens from the polypoid a. Mucinous glands resembling pyloric glands in the lamina propria (arrow) stomach (original magnification X100); b. Higher power view of mucinous glands (original magnification X400)

Keywords: Acute abdomen, heterotopic gastric mucosa, intussusception

Anahtar kelimeler: Akut karın, heterotopik mide mukozası, invajinasyon

Ethics

Peer-review: Externally peer-reviewed.

Financial Disclosure: The author declared that this study received no financial support.

References

1. Boybeyi O, Karnak I, Güçer S, Orhan D, Senocak ME. Common characteristics of jejunal heterotopic gastric tissue in children: a case report with review of the literature. *J Pediatr Surg* 2008;43(7):e19-22.
2. Yu L, Yang Y, Cui L, Peng L, Sun G. Heterotopic gastric mucosa of the gastrointestinal tract: prevalence, histological features, and clinical characteristics. *Scand J Gastroenterol* 2014;49(2):138-144.
3. Hammers YA, Kelly DR, Muensterer OJ, Hardin WD Jr, Saeed SA, Mroczek-Musulman EC. Giant polypoid gastric heterotopia with ectopic thyroid tissue: unusual cause of jejuno-jejunal intussusception. *J Pediatr Gastroenterol Nutr* 2007;45(4):484-477.