



Association Between Left Sided Inguinal Hernia and Varicocele

Sol Taraflı İnguinal Herninin Varikosel ile İlişkisi

✉ Musa Atay

University of Health Sciences Turkey, İstanbul Bağcılar Training and Research Hospital, Clinic of Radiology, İstanbul, Turkey

Abstract

Objective: The aim of this study was to investigate the relationship between left sided inguinal hernia and varicocele.

Method: Between July and October 2022, 60 patients with left inguinal hernia (group 1) and 60 patients without hernia (group 2, control group) were included in our prospective study. Those with a history of right inguinal hernia, left epididymoorchitis, scrotal surgery or inguinal hernia surgery were not included in the study. The patients were evaluated for the presence of left varicocele. Grade of the varicocele, the diameters of the pampiniform plexus veins, and the neck diameter of the hernia were measured.

Results: There were 120 male patients in our study (group 1 n=60, group 2 n=60). While the age range of the patients with hernia was 23-60 years (mean age: 36±8.4 years), the age range of the patients without hernia was 20-58 years (mean age: 33±9.5 years). There was no statistically significant difference between the groups in terms of age distribution (p=0.89). While the incidence of varicocele was 58.3% (35/60) in group 1, it was 23.3% (14/60) in group 2 [relative risk 2.5 (95% confidence interval (CI) (1.507, 4.147))] and odds ratio of 4.6 [95% CI (2.091, 10.118)]. While the median grade of varicocele was 1 in group 1, it was 0 in group 2, and a statistically significant difference was found (p<0.001). Diameters of pampiniform plexus veins were found to be significantly larger in group 1 [2.402, standard deviation (SD)=0.586 vs 1.867, SD=0.375, p<0.001].

Conclusion: The risk of varicocele increases in patients with left sided inguinal hernia.

Keywords: Infertility, inguinal hernia, hernia, ultrasound, varicocele

Öz

Amaç: Bu çalışmanın amacı sol taraflı kasık fıtığı ile varikosel arasındaki ilişkiyi araştırmaktır.

Yöntem: Temmuz-Ekim 2022 tarih aralığında, sol inguinal herni saptadığımız 60 hasta (grup 1) ve herni saptamadığımız 60 hasta (grup 2, kontrol grubu) prospektif çalışmamıza dahil edildi. Sağ inguinal hernisi, sol epididimoorşit öyküsü, skrotal cerrahi veya inguinal herni cerrahisi öyküsü olanlar çalışma kapsamına alınmadı. Olgular sol varikosel varlığı açısından değerlendirildi. Varikosel derecesi, pampiniform pleksus ven çapı ve herni kesesinin boyun çapı ölçüldü.

Bulgular: Çalışmamızda toplam 120 erkek hasta mevcuttu (grup 1 n=60, grup 2 n=60). Hernisi olan hastaların yaş aralığı 23-60 yıl iken (ortalama yaş: 36±8,4 yıl), hernisi olmayan hastaların yaş aralığı 20-58 yıl (ortalama yaş: 33±9,5 yıl) idi. Yaş dağılımı açısından gruplar arasında istatistiksel anlamlı farklılık saptanmadı (p=0,89). Grup 1'de varikosel sıklığı %58,3 (35/60) görülürken, grup 2'de %23,3 (14/60) saptandı [rölatif risk 2,5 (%95 güven aralığı (GA) (1,507, 4,147))] ve olasılık oranı 4,6 [%95 GA (2,091, 10,118)]. Grup 1'de ortalama varikosel derecesi 1 iken, grup 2'de ise 0 saptanmış olup istatistiksel anlamlı farklılık saptandı (p<0,001). Pampiniform pleksus ven çapları grup 1'de anlamlı olarak daha geniş bulunmuştur [2,402, standart sapma (SS)=0,586 vs. 1,867, SS=0,375, p<0,001].

Sonuç: Sol inguinal hernisi olan hastalarda varikosel riski artmaktadır.

Anahtar kelimeler: İnfertilite, inguinal herni, herni, ultrason, varikosel

Introduction

Inguinal hernia (IH) is the most common abdominal wall hernia (80%). There is male predominance with a male:female ratio of 7:1. The most common symptom is swelling

and pain in the groin, and testicular pain can be seen in male patients. Risk factors include obesity, pregnancy, collagen vascular diseases, smoking and chronic obstructive pulmonary disease (1). Varicocele is a condition found in 15% of all males, 35% of males with primary infertility and



Address for Correspondence: Musa Atay, University of Health Sciences Turkey, İstanbul Bağcılar Training and Research Hospital, Clinic of Radiology, İstanbul, Turkey

E-mail: musaatay@yahoo.com **ORCID:** orcid.org/0000-0001-7750-3093 **Received:** 18.10.2022 **Accepted:** 28.12.2022

Cite this article as: Atay M. Association Between Left Sided Inguinal Hernia and Varicocele. Bagcilar Med Bull 2023;8(1):1-5

©Copyright 2023 by the Health Sciences University Turkey, Bağcılar Training and Research Hospital
Bagcilar Medical Bulletin published by Galenos Publishing House.

approximately 80% of males with secondary infertility (2). Varicocele is mostly seen on the left side (80-90%) and it has been reported that the opening of the left testicular vein at right angles to the left renal vein and the consequent turbulent flow and increase in back pressure towards the testicular vein play a role in the etiology (3). There are studies reporting that varicocele is associated with IH (4) and connective tissue diseases (5). It has been reported that IH is also associated with collagen vascular diseases and there may be a connection with connective tissue diseases in its etiology (6). In the current study, the frequency and grade of varicocele were determined to be increased in cases with IH.

The purpose of this study was to evaluate the presence of varicocele in patients with left-sided IH. The study hypothesis was that the risk and degree of varicocele would be increased in patients with left-sided IH due to its association with collagen vascular diseases and the compression effect.

Materials and Methods

This prospective study included 60 patients (group 1) who were referred to our ultrasound unit with the suspicion of IH and possible scrotal extension, and were diagnosed with left IH for the first time between July 2022 and October 2022. In addition, 60 patients in the same age range who were referred to the ultrasound unit with same clinical findings and hernia was not detected were included in the study as the control group (group 2).

Patients with right-sided IH were excluded from the study because of other possible underlying retroperitoneal pathologies in terms of varicocele. Patients with comorbidities that may be associated with varicocele such as hyperlipidemia, diabetes mellitus and hyperlipidemia were also excluded from the study, as were those with a history of left epididymo-orchitis, scrotal surgery or IH surgery. Both groups were evaluated for the presence of a left-sided varicocele. During ultrasound examination, the grade of varicocele, diameter of pampiniform plexus veins and neck diameter of the hernia were measured. The groups were compared in respect of statistically significant differences.

All procedures performed in studies involving human participants were in accordance with the ethical standards of the Institutional Research Committee (University of Health Sciences Turkey, Bakırköy Dr. Sadi Konuk Training and Research Hospital, reference number: 2022-14-10, 18/07/2022) and with the 1964 Helsinki Declaration and

its later amendments or comparable ethical standards. All individuals were fully informed and gave their written informed consent.

Imaging Technique

The patient was asked to undress and lie on his back with his legs together. A towel was placed between the legs and under the scrotum to support the testicles. The penis was placed on the abdomen and only the scrotum was exposed. A linear array 7-15 MHz transducer (Samsung RS85) was used. Transverse and longitudinal views of each testis were obtained. The inguinal canal was included in the examination. Color Doppler and spectral Doppler were used for varicocele. At least one image showing both testicles was acquired on the same image to compare overall testicular echogenicity.

Evaluation of IH

The presence of adipose tissue or intestinal loop herniation into the left inguinal canal at rest or during the Valsalva maneuver was examined. The neck diameter of the hernia was measured.

Evaluation of Varicocele

Presence of varicocele was examined in both the supine and standing positions. Diameter of pampiniform plexus vein was measured. Largest vein diameter, irrespective of location, being more than 2 mm is considered abnormal. The presence of reflux was examined during the Valsalva maneuver. Varicocele was classified into five grades according to the Sarteschi classification (7).

Statistical Analysis

All statistical analyses were performed using a commercially available SPSS release 20.0 software package (SPSS Inc., Chicago, IL, USA). In statistical analysis, Pearson chi-squared test (χ^2), Mann-Whitney U test where appropriate was used to compare the distribution of categorical data relative to each other. One-Way ANOVA test was used in terms of age distribution of the groups. A p-value <0.05 was considered to show a statistically significant result.

Results

Evaluation was made of a total of 120 male patients, as 60 in group 1, and 60 in group 2. The mean age was 36 ± 8.4 years (range, 23-60 years) in group 1, and 33 ± 9.5 years (range, 20-58 years) in group 2. There was no statistically significant difference between the groups in terms of age distribution ($p=0.89$).

The incidence of varicocele was determined as 58.3% (35/60) in group 1, and 23.3% (14/60) in group 2 (Table 1). The relative risk was calculated as 2.5 [95% confidence interval (CI) (1.507, 4.147)] and the odds ratio as 4.6 [95% CI (2.091, 10.118)] (Figure 1).

The median grade of varicocele was 1 in group 1, and 0 in group 2, and the difference was determined to be statistically significant ($p < 0.001$) (Figure 2).

The Mann-Whitney U test was used to compare the diameter of the pampiniform plexus vein, which was found to be significantly larger in the hernia group [2.402, standard deviation (SD)=0.586 vs. 1.867, SD=0.375, $p < 0.001$] (Table 2).

No significant correlation was determined between the diameter of the hernia neck and the diameter of the pampiniform plexus vein in the hernia group ($r = -0.06$, $p = 0.66$).

In the hernia group, no significant difference was determined between patients with and without varicocele in terms of diameter of the neck (mean diameter was 13.5 mm in those with varicocele and 14.9 mm in those without varicocele, $p = 0.27$) (Table 3).

Table 1. Distribution of hernia and varicocele

	Varicocele (+) n=49	Varicocele (-) n=71
Hernia (+) n=60	35 (58.3%)	25 (41.7%)
Hernia (-) n=60	14 (23.3%)	46 (76.7%)

Discussion

The principal findings of this study demonstrate that the risk of varicocele increases in patients with left sided IH. An increased prevalence of varicocele was seen in patients with IH (58.3%) compared to the prevalence of varicocele in patients without IH (23.3%) and the prevalence in the general population (15%) reported in the literature (8-10). Some studies in the literature have investigated diseases that may be associated with varicocele. El-Tatawy et al. (11) reported an increased risk of varicocele over time in adolescent patients with a history of epididymo-orchitis. Wang et al. (12) investigated the relationship between varicocele and vascular diseases and stated that the risk of heart disease, diabetes and hyperlipidemia was increased in patients with varicocele, especially in symptomatic individuals. It was suggested that the decrease in testosterone level, hypogonadism and oxidative stress developing in the background of varicocele may increase the risk of metabolic and vascular diseases. In a study by Tsukanov et al. (13), a high rate (87.2%) of connective tissue dysplasia findings such as asthenic body type, arrhythmia, arterial hypotension and disturbed tooth growth were found in cases with varicocele, and it was stated that varicocele may be a manifestation of connective tissue dysplasia. Similarly, Serra et al. (5) stated that the detection of varicocele at a young age may be an early marker for the progression of a connective tissue-related disease such as IH and chronic venous disease at older ages.

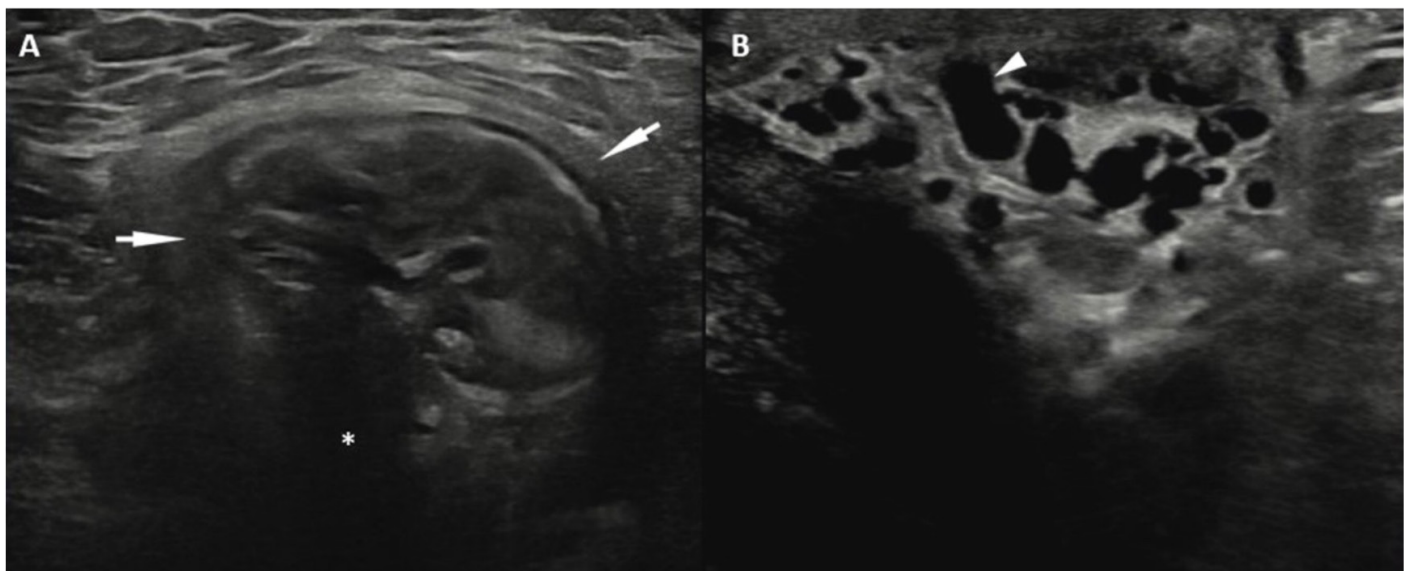


Figure 1. Ultrasound examination shows marked inguinal hernia (A, arrows) with neck of hernia (A, star) and accompanying enlarged pampiniform plexus veins consistent with varicocele (B, arrowhead)

The only study in the literature [Albuz et al. (4)], conducted with a similar method to the current study, investigated the role of IH in the development of varicocele in the young age group and found that the risk of varicocele was increased in hernia cases. It was stated that the development of varicocele may be secondary to compression of the testicular vein, or in some cases, to some enzymatic or biochemical disorders that may play a role in the development of both hernia and varicocele. However, that study (4) was retrospective, right hemiscrotum was included in the study (due to possible non-hernial pathologies that may cause secondary varicocele), and its surgical history was not known were disadvantages. Therefore, the current study can be considered more specific research. In addition, the neck diameter of the hernia, the diameter of pampiniform plexus veins and grade of varicocele were examined in the current study, and vein diameter and mean grade of varicocele were found to be higher in cases of IH.

When evaluated together with the literature (4,5,13), we thought that the increased risk of varicocele in cases of hernia may be secondary to the high risk of connective tissue-related disease in these cases or compression

of testicular vein due to IH or both. Physiopathology is remain unclear. Although the treatment of varicocele has not been standardised, it is usually determined according to the fertility status of the patient. In the current study, since the grade of varicocele was higher in patients with IH, it was assumed that the risk of infertility may be higher in these patients. Therefore, hernia can be a guiding finding in terms of varicocele treatment. There is a need for further studies in this direction supported by clinical and laboratory findings.

Study Limitations

Our study has some limitations. The first is the limited number of patients, and second is the lack of clinical and laboratory characteristics.

Conclusion

The risk of varicocele increases in patients with left-sided IH. As the higher grade of varicocele in these patients poses a risk for infertility, hernia may be a guide for treatment of varicocele which does not have a standard treatment. More comprehensive studies supported by clinical findings are needed.

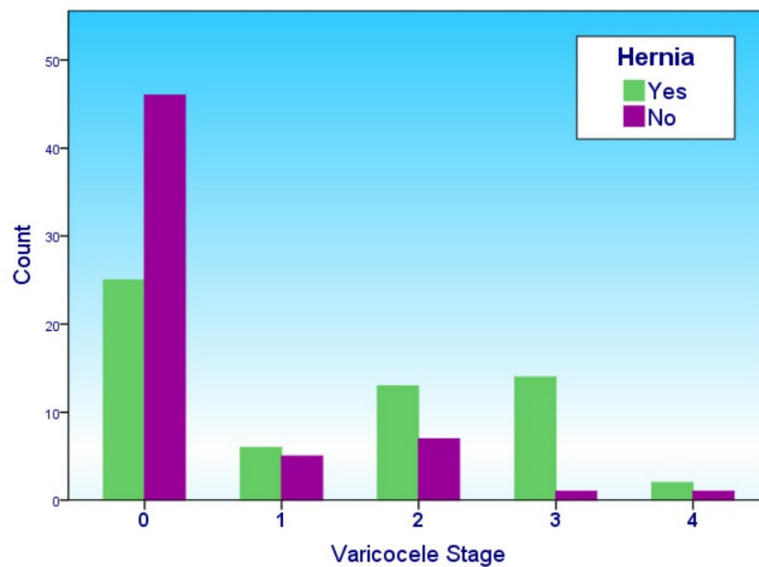


Figure 2. The present graphic shows grades of varicocele in patients with and without inguinal hernia

Table 2. Mean diameter of pampiniform plexus vein (DPPV) with standard deviation (SD) in patients with and without hernia

	DPPV	SD
Hernia (+) n=60	2.402 mm	0.586
Hernia (-) n=60	1.867 mm	0.375
p-value	p<0.001	

Table 3. Mean diameter of the neck of hernia (DNH) in patients with and without varicocele in the hernia group

	Varicocele (+) n=14	Varicocele (-) n=46
DNH	13.5 mm	14.9 mm
p-value	p=0.27	

Ethics

Ethics Committee Approval: All procedures performed in studies involving human participants were in accordance with the ethical standards of the Institutional Research Committee (University of Health Sciences Turkey, Bakırköy Dr. Sadi Konuk Training and Research Hospital, reference number: 2022-14-10, 18/07/2022) and with the 1964 Helsinki Declaration and its later amendments or comparable ethical standards.

Informed Consent: All individuals were fully informed and gave their written informed consent.

Peer-review: Internally and externally peer-reviewed.

Financial Disclosure: The author declared that this study received no financial support.

References

1. Suzuki S, Furui S, Okinaga K, Sakamoto T, Murata J, Furukawa A, et al. Differentiation of femoral versus inguinal hernia: CT findings. *AJR Am J Roentgenol* 2007;189(2):W78-83.
2. Pauroso S, Di Leo N, Fulle I, Di Segni M, Alessi S, Maggini E. Varicocele: Ultrasonographic assessment in daily clinical practice. *J Ultrasound* 2011;14(4):199-204.
3. Cauni V, Ciofu I, Stoica C, Balescu I, Bacalbasa N, Persu C. Doppler Ultrasonography - An Important Tool in Managing Patients With Varicocele and Secondary Infertility. *In Vivo* 2022;36(5):2392-2399.
4. Albuz Ö, Okçelik S, İnce S, Oğulluk M, Sarıkaya S, Ozan H. Is inguinal hernia a risk factor for varicocele in the young male population? *Arch Esp Urol* 2019;72(7):697-704.
5. Serra R, Buffone G, Costanzo G, Montemurro R, Perri P, Damiano R, et al. Varicocele in younger as risk factor for inguinal hernia and for chronic venous disease in older: preliminary results of a prospective cohort study. *Ann Vasc Surg* 2013;27(3):329-331.
6. Fitzgibbons RJ Jr, Forse RA. Clinical practice. Groin hernias in adults. *N Engl J Med* 2015;372(8):756-763.
7. Tsili AC, Bougia CK, Pappa O, Argyropoulou MI. Ultrasonography of the scrotum: Revisiting a classic technique. *Eur J Radiol* 2021;145:110000.
8. Kibar Y, Seckin B, Erduran D. The effects of subinguinal varicocelectomy on Kruger morphology and semen parameters. *J Urol* 2002;168(3):1071-1074.
9. Alsaikhan B, Alrabeeah K, Delouya G, Zini A. Epidemiology of varicocele. *Asian J Androl* 2016;18(2):179-181.
10. Dubin L, Amelar RD. Etiologic factors in 1294 consecutive cases of male infertility. *Fertil Steril* 1971;22(8):469-474.
11. El-Tatawy H, Elsakka AM, Tawfik A, Ghaith A, Gameel TA, Soliman MG. Gonadal infection: a risk factor for the development of adolescent varicocele. *Ann Pediatr Surg* 2017;13:213-216.
12. Wang NN, Dallas K, Li S, Baker L, Eisenberg ML. The association between varicoceles and vascular disease: an analysis of U.S. claims data. *Andrology* 2018;6(1):99-103.
13. Tsukanov AY, Semikina SP, Mustafayev RF. Varicocele as a manifestation of connective tissue dysplasia. *Urologicheskie vedomosti* 2019;9(2):11-16.