



The Course of COVID-19 in a Patient with Congenital Neutropenia: A Case Report

Konjenital Nötropenili Bir Hastada COVID-19 Hastalığı: Bir Olgu Sunumu

Sezin Naiboğlu¹, Mehmet Halil Çeliksoy¹, Ayşegül Öztürk Kaymak², Hasan Önal³, Işlay Turan¹, Selami Ulaş¹, Çiğdem Aydoğmuş¹

¹University of Health Sciences Turkey, Başakşehir Çam and Sakura City Hospital, Clinic of Pediatric Allergy and Immunology, İstanbul, Turkey

²Düzen Laboratories Group, Department of Medical Genetics, Ankara, Turkey

³University of Health Sciences Turkey, Başakşehir Çam and Sakura City Hospital, Clinic of Pediatric Metabolism, İstanbul, Turkey

Abstract

Coronavirus disease-2019 (COVID-19) is a respiratory illness caused by severe acute respiratory syndrome-coronavirus-2. Although it is primarily a respiratory illness, there is growing evidence that it also affects the digestive system and manifests itself through various symptoms such as loss of appetite, diarrhea, nausea and vomiting. In this context, this case report features a 14-year-old female patient with congenital neutropenia who became infected with COVID-19, yet had no respiratory system involvement. Instead, the patient developed primarily gastrointestinal tract involvement and secondarily syndrome of inappropriate antidiuretic hormone secretion.

Keywords: Coronavirus, congenital neutropenia, COVID-19, HAX-1 mutation, primary immunodeficiency

Öz

Koronavirüs hastalığı-2019 (COVID -19), şiddetli akut solunum sendromu-koronavirüs-2'nin neden olduğu bir solunum yolu hastalığıdır. Mart 2020'de Dünya Sağlık Örgütü tarafından pandemi olarak sınıflandırılan bir acil halk sağlığı durumu haline geldi. Öncelikle bir solunum yolu hastalığı olmasına rağmen, sindirim sistemini de etkilediğine ve iştahsızlık, ishal, mide bulantısı ve kusma gibi çeşitli semptomlarla kendini gösterdiğine dair artan kanıtlar vardır. Bu olgu sunumunda, solunum sistemi tutulumu olmayan, sadece gastrointestinal sistem tutulumu ve sekonder uygunsuz antidiüretik hormon salgılanması sendromu gelişen doğuştan nötropenili 14 yaşında bir kız hasta sunulmaktadır.

Anahtar kelimeler: COVID-19, HAX-1 mutasyonu, konjenital nötropeni, koronavirüs, primer immün yetmezlik

Introduction

Coronavirus disease-2019 (COVID-19) is a respiratory illness caused by severe acute respiratory syndrome-coronavirus-2 (SARS-CoV-2). First cluster of COVID-19 cases were reported in the city of Wuhan located in Hubei Province of China on December 31st, 2019. COVID-19 outbreak was then declared an epidemic, i.e., a public health emergency of international concern, on January 30th, 2020, and later a pandemic, i.e., a public health emergency of global concern, on March 11th, 2020, by the World Health Organization. Clinical findings associated with the disease

tend to vary from person to person. While some COVID-19 patients were asymptomatic, others had died due to COVID-19-induced acute respiratory distress syndrome (ARDS). The course of the disease is particularly severe in older men. Other risk factors associated with a poor prognosis are diabetes mellitus, hypertension, chronic respiratory disease, cancer, and cardiovascular disease (1).

This case report features a 14-year-old female congenital neutropenia patient who became infected with COVID-19 and presented with atypical clinical findings such as acute gastroenteritis and syndrome of inappropriate antidiuretic



Address for Correspondence: Sezin Naiboğlu, University of Health Sciences Turkey, Başakşehir Çam and Sakura City Hospital, Clinic of Pediatric Allergy and Immunology, İstanbul, Turkey

Phone: +90 506 961 37 36 **E-mail:** sezin_ctnol@hotmail.com **ORCID:** orcid.org/0000-0002-9593-1136 **Received:** 26.07.2022 **Accepted:** 25.12.2022

Cite this article as: Naiboğlu S, Çeliksoy MH, Öztürk Kaymak A, Önal H, Turan I, Ulaş S, Aydoğmuş Ç. The Course of COVID-19 in a Patient with Congenital Neutropenia: A Case Report. Bagcilar Med Bull 2023;8(1):94-98

©Copyright 2023 by the Health Sciences University Turkey, Bagcilar Training and Research Hospital
Bagcilar Medical Bulletin published by Galenos Publishing House.

hormone secretion (SIADH), but without respiratory system involvement, similar to most COVID-19 cases reported in the literature.

Case Report

A 14-year-old female patient applied to the emergency service with complaints of loss of appetite, abdominal pain, and diarrhea that have been going on for the last three days. Her anamnesis indicated that she underwent tympanomastoidectomy for recurrent otitis media, suffered from bilateral hearing loss, was observed for chronic neutropenia, and was receiving trimethoprim-sulfamethoxazole prophylaxis. Molecular examination indicated a homozygous hematopoietic cell-specific protein 1-related protein X-1 mutation (Figure 1a). Her physical examination revealed that her general condition was poor, and she was mildly to moderately dehydrated. She had no fever. Examination of the respiratory system did not reveal any features. The patient, who had right lower quadrant pain on abdominal examination, did not have organomegaly. No pathology was noted on abdominal ultrasonography. The results of the complete blood count test indicated leukopenia and neutropenia. C-reactive protein, one of the markers of infection, was measured as 220 mg/dL. The patient was hospitalized with a diagnosis of congenital neutropenia and acute gastroenteritis. Given that the general condition of the patient, who had no fever,

was not very good, cefepime treatment and intravenous (IV) fluid therapy were initiated. The results of the SARS-CoV-2 polymerase chain reaction test performed using patient's nasopharyngeal aspirate taken on the second day of hospitalization came out negative. Thoracic tomography of the patient did not reveal any features. Her vomiting and diarrhea symptoms did not regress. No pathogenic bacteria grew in the patient's stool culture. *C. difficile*, *E. histolytica*, *rotavirus*, and *adenovirus* were not detected in the microbiological examinations of the stool. The patient's laboratory results are summarized in Table 1. The patient had persistent abdominal tenderness. No air-fluid levels were observed on direct radiography of the abdomen taken in the standing position, yet the bowel loops were pale. Abdominal tomography indicated an increase in adipose tissue at the level of the ascending colon as well as thickening of the peritoneum. Surgical pathology was not considered. Metronidazole was added to patient's treatment due to persistent abdominal pain. Given her severe neutropenia, persistent diarrhea and poor condition in general, she was started on subcutaneous granulocyte colony stimulating factor (G-CSF) treatment at a dose of 10 mcg/kg/day on the sixth day of hospitalization. The patient's serum sodium level, whose diarrhea persisted, was 131 mEq/L (135-145). Patient's hyponatremia persisted despite adequate IV fluid intake. High urinary sodium excretion was noted (191 mEq/L vs. regular value of <20 mEq/L). The patient was diagnosed with SIADH, and subsequently subjected to fluid




Figure 1a

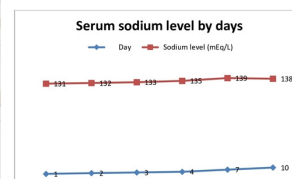


Figure 1b: Distribution of the patient's serum sodium level by days. From the third day, the patient's fluid intake was restricted.

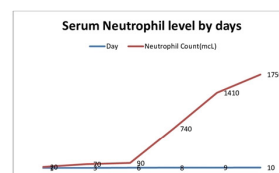


Figure 1c: Distribution of the patient's serum neutrophil level by days. Subcutaneous G-CSF was started at a dose of 10 mcg/kg on the sixth day of hospitalization. mcL: microliter

Figure 1a. A homozygous mutation of c.130_130insA, (p.W44X), (rs1572018284) in the *HAXI* gene was detected. A single nucleotide insertion occurred between positions 130 and 131 in the coding region. A single nucleotide insertion and a die-shifting mutation at position 44 of the protein resulted in a stop codon in the same codon. The RS number reported in the NCBI dbSNP short genetic variations and ClinVar databases has been classified as a pathogenic allele, and Varsome has classified it as a pathogenic. **Figure 1b)** Distribution of the patient's serum sodium level by the time elapsed in days. The patient's fluid intake was restricted starting from the third day of hospitalization. **Figure 1c)** Distribution of the patient's serum neutrophil count by the time elapsed in days. Subcutaneous G-CSF treatment was started at a dose of 10 mcg/kg on the sixth day of hospitalization

mcL: Microliter

Table 1. Characteristics of patients with congenital neutropenia

Parameter	Measurement
White blood cell (1.000/uL)	2.12 (4.19-9.43)
Hemoglobin (g/dL)	9.1 (10.8-13.3)
Platelet (1.000/uL)	298 (150-400)
Total lymphocyte count (1.000/uL)	1.05 (1.16-3.33)
Total neutrophil count (1.000/uL)	0.02 (1.82-7.47)
C-reactive protein (mg/L)	202.5 (0-5)
Erythrocyte sedimentation rate (mm/h)	68 (0-15)
Alanine transaminase (U/L)	2 (0-37)
Aspartate transaminase (U/L)	10 (0-27)
Urea (mg/dL)	25.5 (10.7-38.5)
Uric acid (mg/dL)	5.8 (2.4-5.7)
Creatinine (mg/dL)	0.43 (0.5-0.9)
Sodium (mEq/L)	131 (138-145)
Potassium (mEq/L)	3.59 (3.4-4.7)
Clor (mEq/L)	99 (97-107)
Calcium (mg/dL)	8.28 (8.4-10.2)
Magnesium (mg/dL)	1.78 (1.7-2.2)
Albumin (g/L)	33 (32-45)
Total protein (g/L)	80 (60-80)
Glucose (mg/dL)	94 (74-106)
Alkaline phosphatase (U/L)	116 (50-117)
GGT (U/L)	10 (5-36)
LDH (U/L)	144 (0-250)
Amylase (U/L)	28 (28-100)
Lipase (U/L)	14 (13-60)
Phosphorus (mg/dL)	3.54 (2.5-4.8)
Troponin T (ng/L)	<3 (<14)
Ferritin (ng/mL)	415 (13-150)
Clinical manifestations	Gastroenteritis, inappropriate ADH syndrome
Abdominal ultrasonography	Grade 1 hepatosteatosis
Thorax computed tomography	Normal
Abdominal computed tomography	Normal
Rotavirus	Negative
Adenovirus	Negative
Clostridium difficile	Negative
Entemobia hystolica	Negative
Stool culture	Negative
Sodium spot (mEq/L), in the urine	191.6 (<20)
D-dimer, quantitative (microgram FEU/mL)	1.18 (0-0.5)
Fibrinogen (mg/dL)	428 (193-412)
Blood culture	Negative

LDH: Lactate dehydrogenase, GGT: Gamma-glutamyl transferase, ADH: Antidiuretic hormone

restriction. The patient, who had no fever and whose serum sodium levels returned to normal and absolute neutrophil count increased with treatment with G-CSF during follow-up, was discharged (Figures 1b, c).

Discussion

The coronavirus that causes COVID-19, also known as SARS-CoV-2, is an enveloped, single-stranded RNA virus from the beta-coronavirus subfamily. Severe COVID-19 is usually associated with ARDS and multiorgan failure (2). The most commonly reported clinical symptoms associated with COVID-19 are fever, fatigue, and dry cough. A small percentage of patients infected with COVID-19 present with gastrointestinal symptoms, the most common one being anorexia followed by diarrhea, nausea, and vomiting. The prevalence of gastrointestinal symptoms in COVID-19 patients is 17.6%. COVID-19 patients presenting with only gastrointestinal symptoms are usually diagnosed late, and gastrointestinal involvement is often associated with a poor prognosis (3).

There are several studies in the literature that demonstrated a relationship between primary immunodeficiencies (PIDs) and COVID-19 disease. It was reported that the course of COVID-19 disease in patients with agammaglobulinemia without B-cells is milder than patients with common variable immunodeficiency (CVID) whose B-cells are dysfunctional (1). Based on this finding, the authors of the said study suggested that the absence of B-cells prevents cytokine storm and inflammation and provides an advantage for patients with agammaglobulinemia (1). It has been established that COVID-19 infection has a severe course in patients with PID who have disorders in the antiviral pathway of the innate immune system, e.g., toll-like receptor 3, toll-like receptor 7, or interferon regulatory factor 7, or in the interferon pathway (human interferon alpha/beta receptor chain 2). It has been previously reported that IV immunoglobulin therapy may have a protective effect against COVID-19 in patients with PID (2).

In a multicenter study conducted with COVID-19 patients with neutropenia along with other PIDs such as CVID and phosphoacetylglucosamine mutase 3 deficiency, Meyts et al. determined that neutrophils play a minimal role in the development of immunity against COVID-19 infection based on the observation that the course of COVID-19 in children with chronic granulomatous disease was mild (4). However, cases of congenital neutropenia with COVID-19 are limited to case reports in the literature (5). Vignesh et al. (5) reported COVID-19 infection in a patient with

congenital neutropenia who had pulmonary involvement and respiratory distress but did not require mechanical ventilation. Previous studies have reported that the use of G-CSF for febrile neutropenia in adult patients with malignancies exacerbated respiratory symptoms and cytokine storm due to acute COVID-19 infection (6). In comparison, the patient presented herein had only gastrointestinal tract involvement and no respiratory findings. Her chest examination and thoracic computed tomography scan did not reveal any abnormal finding. The patient was started on cefepime for empirical treatment but not G-CSF at first since she had no fever. Nevertheless, G-CSF treatment had to be started on the sixth day of hospitalization since her general condition was deteriorating as also indicated by the increase in her neutrophil count. The G-CSF treatment resulted in an improvement in patient's general condition and her absolute neutrophil count returned to normal levels by tenth day of hospitalization.

Hyponatremia (<135 mmol/L) is the most common electrolyte disturbance in COVID-19 patients and is generally associated with poor prognosis. Although there are many factors that cause hyponatremia, the most common cause is SIADH, which occurs in approximately 40-50% of patients. This rate may increase in brain injury, subarachnoid hemorrhage, and pneumonia (7). In comparison, the serum sodium level of the patient presented herein was 131 mEq/L at the time of admission. Initially, it was thought that the hyponatremia might be due to diarrhea, and, therefore, the patient was given fluids. Subsequently, given that her hyponatremia did not improve despite fluid intake, her urine sodium level was measured considering that she might have SIADH. Accordingly, the patient, who had high urinary sodium level, was subjected to fluid restriction from the third day of hospitalization, and then her serum sodium level returned to normal.

SARS-CoV-2 activates angiotensin-converting enzyme 2 receptors in the gut, leading to inflammation and diarrhea. A high viral load due to SARS-CoV-2 causes intestinal problems in the early phase of COVID-19, whereas a cytokine storm affecting T and B-cells occurs in the late phase of COVID-19. In parallel, in the late phase, the intestinal symptoms regress, the respiratory tract is affected, and ARDS emerges (8). In comparison, the T and B-cell counts of the patient presented herein were normal. There are insufficient data in the literature on the course of COVID-19 disease in patients with congenital neutropenia. In this context, the findings of this case report featuring a 14-year-old female COVID-19 patient

who had no respiratory involvement and presented with only gastrointestinal involvement and SIADH would likely contribute to the literature in that regard. Nevertheless, further studies are needed on the prognosis of COVID-19 disease in patients with congenital neutropenia.

Ethics

Informed Consent: Informed consent was obtained.

Peer-review: Externally and internally peer-reviewed.

Authorship Contributions

Concept: M.H.Ç., S.N., Design: M.H.Ç., S.N., Data Collection or Processing: M.H.Ç., S.N., A.Ö.K., H.Ö., I.T., S.U., Ç.A., Analysis or Interpretation: M.H.Ç., S.N., A.Ö.K., H.Ö., I.T., S.U., Ç.A., Drafting Manuscript: M.H.Ç., S.N., Critical Revision of Manuscript: M.H.Ç., S.N., Technical and Material Support: M.H.Ç., S.N., A.Ö.K., H.Ö., I.T., S.U., Ç.A., Writing: M.H.Ç., S.N., A.Ö.K., H.Ö., I.T., S.U., Ç.A.

Conflict of Interest: No conflict of interest was declared by the authors.

Financial Disclosure: The authors declared that this study received no financial support.

References

1. Babaha F, Rezaei N. Primary Immunodeficiency Diseases in COVID-19 Pandemic: A Predisposing or Protective Factor? *Am J Med Sci* 2020;360(6):740-741.
2. Liu BM, Hill HR. Role of Host Immune and Inflammatory Responses in COVID-19 Cases with Underlying Primary Immunodeficiency: A Review. *J Interferon Cytokine Res* 2020;40(12):549-554.
3. Galanopoulos M, Gkeros F, Doukatas A, Karianakis G, Pontas C, Tsoukalas N, et al. COVID-19 pandemic: Pathophysiology and manifestations from the gastrointestinal tract. *World J Gastroenterol* 2020;26(31):4579-4588.
4. Meyts I, Buccioli G, Quinti I, Neven B, Fischer A, Seoane E, et al. Coronavirus disease 2019 in patients with inborn errors of immunity: An international study. *J Allergy Clin Immunol* 2021;147(2):520-531.
5. Vignesh P, Mondal S, Sudhakar M, Sharma YK, Bansal A, Singh M, et al. SARS-CoV-2 Infection in a Child with Severe Congenital Neutropenia. *J Clin Immunol* 2021;41(6):1165-1168.
6. Nawar T, Morjaria S, Kaltsas A, Patel D, Perez-Johnston R, Daniyan AF, et al. Granulocyte-colony stimulating factor in COVID-19: Is it stimulating more than just the bone marrow? *Am J Hematol* 2020;95(8):E210-E213.
7. Gheorghe G, Ilie M, Bungau S, Stoian AMP, Bacalbasa N, Diaconu CC. Is There a Relationship between COVID-19 and Hyponatremia? *Medicina (Kaunas)* 2021;57(1):55.
8. Villapol S. Gastrointestinal symptoms associated with COVID-19: impact on the gut microbiome. *Transl Res* 2020;226:57-69.